

# The Evolution of Gastrocnemius – Soleus Lengthening in the Treatment of Acquired Achilles Equinus

---

John S. Early, MD

## Introduction

The recognition and treatment of non-spastic equinus in the face of corrective surgery about the foot and ankle has taken decades to reach its present state. While the interplay between the gastrocnemius and soleus muscle in the generation of ankle equinus has been recognized for a long time in the treatment of spastic deformity, those techniques have only recently been successfully introduced for the treatment of non-spastic deformity. Early pioneers such as Vulpius<sup>5</sup>, Strayer<sup>17,18</sup>, Silfversklold<sup>16</sup> and Baumann<sup>8</sup>, developed successful techniques for differentiating and treating distinct types of equinus contracture. Thirty years ago, there was very little acceptance to the idea that neurologically normal individuals could have a clinically significant equinus contracture. Now there are numerous articles describing successful treatment of a wide range of foot and ankle problems with the assistance of a selective release of the gastrosoleus muscle complex<sup>1,2,4,6,8,12-15</sup>. These pathologies include achilles tendinopathy, plantar fasciitis, posterior tibialis dysfunction and metatarsalgia. The key to choosing the correct procedure for gastrosoleus equinus is careful clinical evaluation of the underlying pathology.

## Anatomy

The triceps surae is a two-joint muscle construct that involves the function of both the gastrocnemius and soleus muscles which come together distally to form the achilles tendon<sup>1,2,4,5</sup>. The soleus muscle originates off the posterior head and neck of the fibula and the posterior proximal metaphyseal diaphyseal area of the tibia and is the deeper of the two muscles. Its main function is to plantar flex the ankle and more importantly resist dorsiflexion with forefoot weight bearing. The gastrocnemius is the more superficial muscle of the triceps surae group. It consists of two heads which originate off the posterior medial and posterior lateral metaphyseal areas of the distal femur. It maintains a separate entity from the soleus for the length of the muscle belly and only connects into the soleus aponeurosis distally after the gastrocnemius aponeurosis becomes tendinous only. The attachment is variable as the fibers intermingle for a two to three centimeter length before becoming indistinguishable. The effect of the gastrocnemius on the tension of the achilles insertion is dependent on the knee position. Knee extension is required for maximal tension. With this structure, it is easy to see how each muscle can have an independent effect on any detected equinus.

There is another component of this two-joint muscle anatomy that is rarely mentioned in the literature but may also play a significant role in non-spastic equinus. The plantaris muscle, which is not present 7 % of the time and is of minimal size, is also a two joint muscle<sup>1</sup>. Its origin is just above the lateral gastrocnemius origin on the femur. The plantaris tendon travels dorsal to the soleus and anterior to the gastrocnemius over to the medial side and attaches at the medial insertion site of the achilles tendon on the calcaneus. When present in an equinus contracture it is important to locate and transect it also to obtain maximal improvement.

Structures of importance which can be placed at risk during dissection are different at different levels along the triceps surae muscle group. Proximally the popliteal artery and vein and tibial nerve lie just lateral to the medial head of the gastrocnemius origin and then quickly disappear under the soleus muscle<sup>10</sup>. As they disappear below the gastrocnemius, the small saphenous vein and the medial and lateral sural nerves lie dorsal to the gastrocnemius muscle. The medial sural nerve and small saphenous vein travel down the raphe between the medial and lateral head of the gastrocnemius<sup>1</sup>. The lateral sural branch travels dorsally over the lateral margin of the lateral head of the gastrocnemius until beyond the musculotendinous junction. It merges back into the

medial branch of the sural nerve over the gastrocnemius tendon in a variable pattern between midline and lateral border and can be variable in its depth<sup>21</sup>. The nerve moves laterally and anteriorly at the musculotendinous junction of the soleus muscle. Medially the greater saphenous vein and nerve travel outside the posterior fascia along the soleus muscle belly moving slowly anterior towards the medial malleolus<sup>10</sup>. Depending on the desired surgical level these different structures may come into play in the operative field.

### Techniques for triceps surae lengthening

There are essentially three types of releases for the triceps surae that can influence the passive tension length of the muscle group<sup>5</sup> (Fig 1). Zone 1 goes from the origins of the gastrocnemius to the distal end of the gastrocnemius tendon before it inserts into the soleus aponeurosis. These releases classically named Barouk proximally to Baumann at mid muscle to the Strayer distally all allow for individualized release of the gastrocnemius muscle without change to the soleus tension. However, each has a variable effect of the function of the gastrocnemius muscle. The Barouk lengthens the medial gastrocnemius muscle lever arm at its origin. The Baumann lengthens both the medial and lateral muscle bellies without disturbing either attachment point and the Strayer completely detaches the insertion point of the gastrocnemius potentially having a significant effect on the shape and remaining function of the muscle. At this zone, soleus tension can also be affected if desired by the clinician by releasing the soleus aponeurosis separately.

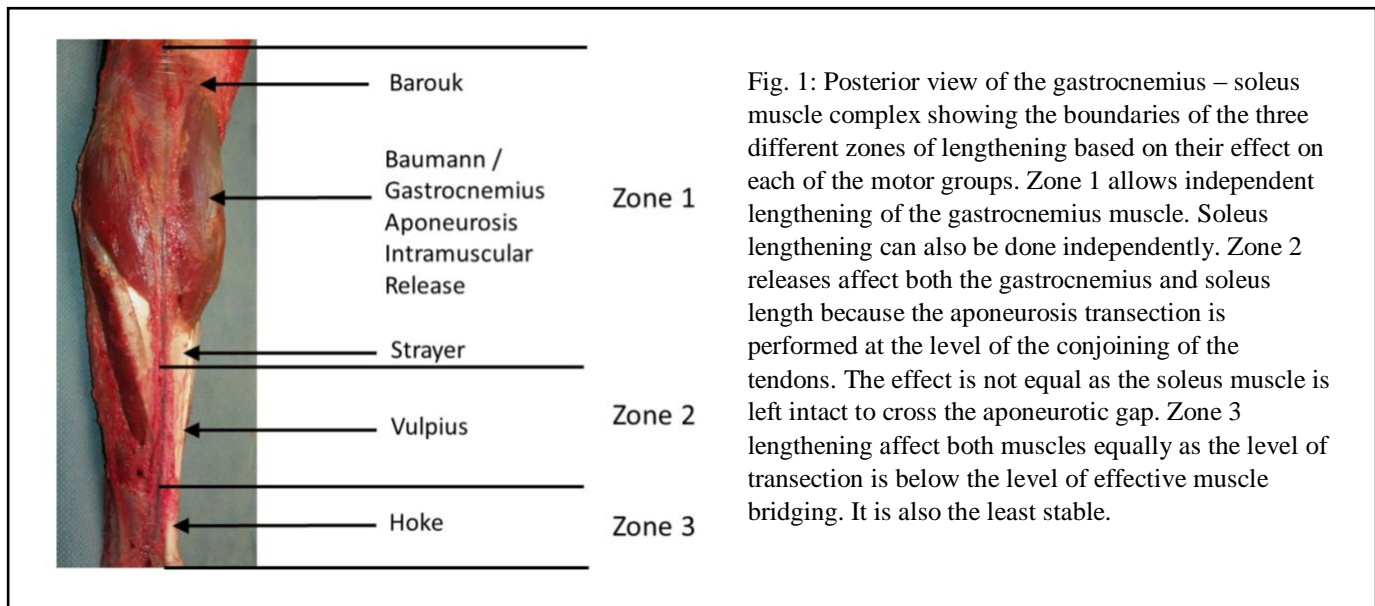


Fig. 1: Posterior view of the gastrocnemius – soleus muscle complex showing the boundaries of the three different zones of lengthening based on their effect on each of the motor groups. Zone 1 allows independent lengthening of the gastrocnemius muscle. Soleus lengthening can also be done independently. Zone 2 releases affect both the gastrocnemius and soleus length because the aponeurosis transection is performed at the level of the conjoining of the tendons. The effect is not equal as the soleus muscle is left intact to cross the aponeurotic gap. Zone 3 lengthening affect both muscles equally as the level of transection is below the level of effective muscle bridging. It is also the least stable.

The Barouk technique involves releasing the aponeurosis of the medial head of the gastrocnemius to decrease gastrocnemius tension<sup>8,15</sup>. It is performed usually prone at the level of the posterior fold in the knee. There is no effect on or access to the soleus at this level. Structures at risk include the popliteal artery and nerve and the small saphenous vein.

The Baumann technique<sup>9</sup> involves locating and separating the interval between the gastrocnemius and soleus muscle bellies from the medial side. It can be supine or prone. It allows for selective lengthening of the gastrocnemius and of the soleus if desired by incising the aponeurosis of the muscle and allowing the muscle fibers themselves to stretch out. By not disrupting either the muscle origin or insertion, this technique does not tend to lead to disrupt muscle function. Access needs to be done at the level where the gastrocnemius muscle is thick. At this level, structures such as the sural nerve are on the dorsal side of the muscle away from the approach and incision. The only structure at risk is the saphenous vein and nerve which lie in the subcutaneous tissue just anterior to the medially based incision.

The Strayer technique involves complete separation of the gastrocnemius tendon from the soleus tendon<sup>16,19,20</sup>. There are techniques which describe suturing it back down higher or leaving it free to retract and find its own place to reattach. This technique while affecting only the gastrocnemius, completely disrupts its motor function and can lead to contour changes in the calf<sup>3</sup>. Classically, it is done through a posterior approach and described in either the prone position or supine with the leg elevated. It has also been described through a medial approach making supine access easier. Structures at risk with this approach are the sural nerve and its branches as it rests on or lateral to the gastrocnemius tendon.

Zone 2 is the area from the conjoining of the gastrocnemius and soleus aponeuroses to the musculotendinous junction of the soleus. Here releasing the gastrocnemius fascia also affects the soleus as part of the release because it disrupts the soleus aponeurosis to a varying extent. This area of lengthening does not allow for selective lengthening of one muscle. The Vulpius is the classic open technique. The modern description of endoscopic releases is generally described in Zone 2 and affects both muscles with their aponeurosis transection. These afford a greater release than Zone 1 but can also have a greater effect on function<sup>15</sup>.

The Vulpius<sup>5,17</sup> technique is performed at the confluence of the gastrocnemius and soleus aponeuroses. Through a posterior approach, the tendon is transected either straight or a “v” shape exposing the underlying soleus muscle. This approach is described with the patient in the prone position. It can also be approached supine, but the leg must be elevated to gain proper visualization. Again, the structures at risk are the small saphenous vein and the sural nerve which overlie the tendon at this level<sup>21,22</sup>.

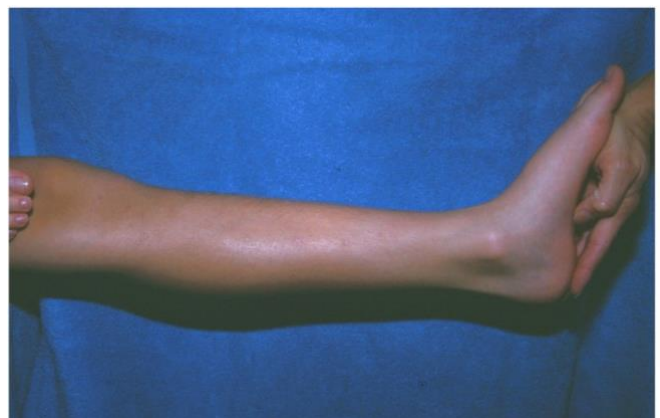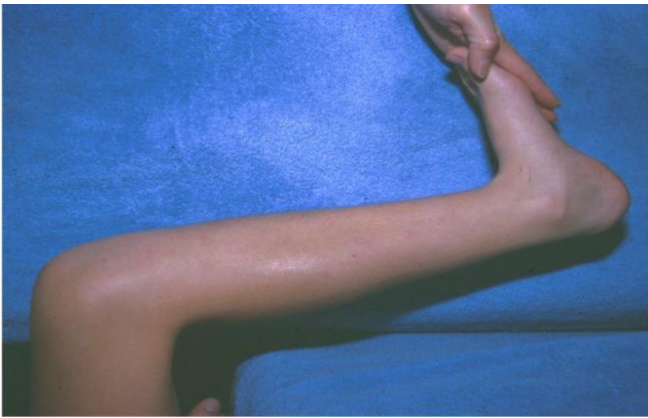Endoscopic releases essentially follow the same method as the open Vulpius technique with a one or two portal approach across the back of the conjoined tendon<sup>6,22</sup>. The main difficulty described is getting all the tendon released and visualization of the soleus muscle belly as evidence of adequate transection.

Zone 3 is from the musculotendinous junction to the insertion into the calcaneus. This area is represented by the classic achilles lengthening whether percutaneous 2 or 3 step cut or open “z” lengthening. Lengthening the achilles in this zone affects both muscles equally without changing their relation to each other. It is also the zone shown by recent studies to be the least stable and most prone to overlengthening<sup>5</sup>.

### **Indication for release**

The key to deciding what level of release is appropriate lies in the clinical evaluation of the muscle group. The test which has become the standard is the Silfverskiöld<sup>2,4,18</sup> test which is a clinical means to evaluate the patient’s passive ability to dorsiflex the ankle looking at each muscle of the complex individually. Our present understanding is that for normal gait progression and ground force pressure distribution weight bearing mechanics need to permit 10-18 degrees of dorsiflexion<sup>2</sup>. The Silfverskiöld test is performed with the patient seated or lying down and the leg relaxed. The test is assessing passive range and will be distorted if the patient assists with any active dorsiflexion. The foot position is critical for accurate assessment. In order to remove the added dorsiflexion which can occur through the position of the subtalar joint, the foot must be held stable in a talonavicular neutral position to lock the subtalar joint from contributing to the perceived dorsiflexion<sup>10</sup>. With the knee relaxed and bent to 90 degrees and the foot controlled in a subtalar neutral position, the ankle dorsiflexion is evaluated (fig 2). Dorsiflexion more than 10 degrees shows the soleus has adequate travel. Inability to get adequate dorsiflexion at this point means there is some involvement of the soleus in the equinus present. Inability to get to neutral when there is no evidence of bony block to dorsiflexion denotes significant soleus involvement.

Fig. 2 A&B: The Silfverskiold test is used to evaluate the presence of gastrosoleus contracture by evaluating the muscles separately. A) With the knee bent and the foot held in talonavicular neutral, the ankle is passively dorsiflexed to judge soleus contracture with respect to ankle dorsiflexion. B) The knee is then straightened, and with the foot held in the same position, the ankle is again passively dorsiflexed. This measures the effect of the gastrocnemius muscle on the limitation of ankle dorsiflexion.




With the foot in the same position the knee is now straightened to full extension. The amount of dorsiflexion measured will demonstrate the extent of gastrocnemius involvement in the weight bearing equinus. Therefore, loss of adequate dorsiflexion only with knee extension displays isolated gastrocnemius contracture without soleus involvement. This would best be treated with a Zone 1 procedure. Inadequate dorsiflexion above neutral with increased loss on knee extension indicates the need for either Zone 1 or a Zone 2 procedure as you are looking to have a lengthening effect on both muscles. For Zone 1 to be effective it would have to have to involve a separate transection of the soleus fascia to allow the muscle fibers to find a new resting length. The full effect of this added procedure, though discussed in the literature, has not been measured clinically. Inability to reach neutral, independent of knee position, many times will require a Zone 3 lengthening, which will have a profound effect on remaining motor strength.

In the non-neurologically compromised patient, the vast majority of equinus deformities are isolated gastrocnemius contractures<sup>2,4</sup> and so should be addressed with only a gastrocnemius altering procedure to preserve normal soleus function. The goal is to pick the procedure in Zone 1 that has the least complications and can easily be performed either as a standalone procedure or in conjunction with other procedures. While the Strayer procedure to date has been the most popular, issues of sural nerve stretch injuries, prolonged weakness or change in calf contour have been reported<sup>3</sup>. The Baumann has been less popular because of visualization. While the interval is easy to find and the complications are minimal, the gastrocnemius muscle is broad at this point and visibility to the lateral border is difficult. Various methods have been described to facilitate this view by borrowing speculums from other specialties to spread the muscles through a small incision<sup>23</sup>.

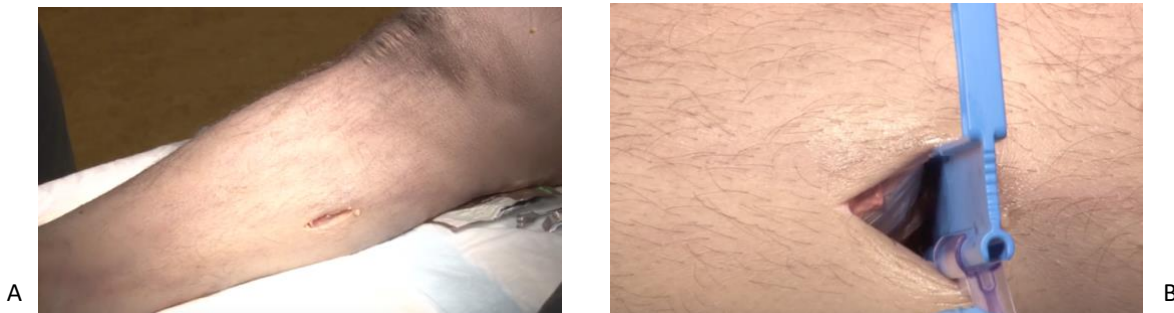The PiroVue<sup>®</sup> Gastrocnemius Recession System. is a recession guide designed to distract and facilitate a controlled gastrocnemius lengthening using a Zone 1 or Baumann medial intramuscular mini-open approach (Fig 3). Its distal end is designed for easy insertion between the gastrocnemius and soleus muscle bellies. A hook at the far end of the recession guide is designed to hook the lateral margin of the gastrocnemius muscle in place as the blade is passed. It also captures the blade at the end of its journey across the muscle aponeurosis to protect it from injuring further tissue. The height of the guide is meant to provide both tension to the muscle belly as well as enhance direct visualization of the aponeurosis to be cut. There is a moveable slide over the beginning of the blade channel which is used to protect the skin and subcutaneous tissue from injury during the insertion of the blade. The device is designed to be a single pass transection of the muscle aponeurosis. The blade and guide should be removed as one unit to avoid injury to surrounding tissue.

Fig. 3: The PiroVue gastrocnemius aponeurosis recession guide shown with the blade part way inserted.



The technique for use requires a 2.5 – 3 cm longitudinal incision on the medial aspect of the calf approximately 2 finger breadths below the posterior edge of the tibia (Fig 4). The distal end of the incision should be at the level where the external gastrocnemius contour just begins to taper into the musculotendinous junction. Blunt, digital dissection is performed through the superficial fat layer to minimize injury to the saphenous vein or tributaries. Upon visualization of the posterior fascia, look for a fatty line between the two muscle masses, the soleus and gastrocnemius. Longitudinal incision of the fascia is done at that point along the length of the skin incision. Again, using blunt digital dissection, locate and release the interval between the solus and gastrocnemius muscle bellies. Visually, aponeurotic tissue should be seen covering both muscles if you are in the correct interval. After creating a clear path to the lateral edge of the gastrocnemius, a quick look for the plantaris tendon on the dorsal surface of the soleus should be undertaken. If located, it should be transected. Next the PiroVue guide is inserted between the soleus and gastrocnemius muscle bellies until the guide can be palpated on the lateral side of the calf. Once the guide is beyond the lateral aspect of the gastrocnemius, the guide is rotated 90 degrees such that the blade channel is facing the gastrocnemius aponeurosis. In order to protect the medial soft tissues and any medial gastrocnemius muscle outside of the aponeurosis, the tissue protector is slid down into place stopping just at the medial edge of gastrocnemius aponeurosis. The gastrocnemius is then placed under tension by dorsiflexing the foot with the knee extended. The PiroVue blade is introduced into the blade channel and slowly slid down the channel to cut the aponeurosis leaving the underlying muscle intact. During the travel of the blade it is important to maintain the gastrocnemius in maximum tension by continuing to dorsiflex the foot. At the end of the pass, the blade is embedded into a protective sheath and the guide rotated 90 degrees and removed. In those cases where the surgeon wishes to make additional gastrocnemius or soleus aponeurosis cuts, the device should be completely removed from the calf and then the blade removed from the guide before re-inserting the guide.

Fig. 4 A&B: The incision is placed on the medial aspect of the calf just above the level of the visible gastrocnemius musculotendinous junction. A) This is the location and view of the superficial fascia on a cadaver model. B) The view of the gastrocnemius fascia once the fascia is incised and the interval between the gastrocnemius and soleus is bluntly developed. The PiroVue guide is inserted at this point.



As with other Zone 1 procedures, this is a stable lengthening. The patient may weight bear as tolerated for isolated procedures. For best results, patients should be placed in an ankle dorsiflexion cast or boot for the first two weeks to maintain maximum gap during early healing. Forcing the knee into extension with walking will help maximize lengthening results. The patient is encouraged to stretch the triceps surae by resting the leg with the knee in full extension. After two weeks, active stretching and advancement of activity as tolerated is encouraged in the isolated cases. When it is performed in combination with other procedures, the protocol is dependent on those procedures.

## Conclusions

Acquired equinus of the triceps surae is now a recognized contributor to many chronic issues in the foot and ankle. In non-neurologic patients, equinus is in the vast majority of cases the result of an isolated gastrocnemius contracture. While there are many described techniques to effectively lengthen the gastrocnemius-soleus complex, with an isolated gastrocnemius, it may be best to effectively lengthen only that muscle. The Baumann procedure with its mid muscle aponeurosis transection, leaving the remainder of the muscle belly in continuity may be the procedure with the least complications. The use of the PiroVue Gastrocnemius Recession System makes the recession of the gastrocnemius aponeurosis quick and simple and minimizes complications.

## References:

1. Abdulmassih S, Phisitkul P, Femino JE, Amendola A; Triceps surae Contracture: Implications for Foot and Ankle Surgery; *J Am Acad Orthop Surg* 21(7): 398 – 407. 2013.
2. Barske HL, DiGiovanni BF, Douglas M, Nawoczenski A; Current Concepts Review: Isolated Gastrocnemius Contracture and Gastrocnemius Recession; *Foot Ankle Int*:33(10); 915-921; 2012.
3. Chimera NJ, Castro M, Manal K; Function and Strength Following Gastrocnemius Recession for Isolated Gastrocnemius Contracture; *Foot Ankle Intl*; 31(5):377 – 384, 2010.
4. DiGiovanni CW, Kuo R, Tejwani N, et al; Isolated Gastrocnemius Tightness; *J Bone Joint Am*; 84(6): 962-970. 2002.
5. Firth GB, McMullan M, Chin T, Ma F, et al; Lengthening of the Gastrocnemius-Soleus Complex: an anatomical and biomechanical study in human cadavers. *JBJS am* 95A (16): 1489-1496. 2013.
6. Gentchos CE, Bohay DR, and Anderson JG; Gastrocnemius Recession as a Treatment for Refractory Achilles Tendinopathy: A Case Report. *Foot Ankle Intl* 29(6): 620-3, June 2008.
7. Grady JF, Kelly C; Endoscopic Gastrocnemius Recession for Treating Equinus in Pediatric Patients; *CORR* 468(4): 1033-1038; 2010.
8. Gurdezi S, Kohls-Gatzoulis J, Solan M; Results of Proximal Medial Gastrocnemius Release for Achilles Tendinopathy; *Foot Ankle Intl*; 34(10)1364- 1369; 2013.
9. Herzenberg JE, Lamm BM, Corwin C, Sekel John; Isolated Recession of the Gastrocnemius Muscle: The Baumann Procedure; *Foot Ankle Intl*; 33(11); 1154-1159; 2007.
10. Johanson MA, DeArment A, Hines K; et al; The Effect of Subtalar Joint Position on Dorsiflexion of the Ankle/ Rearfoot Versus Midfoot/ Forefoot During Gastrocnemius Stretching; *Foot Ankle Intl*; 35(1);63- 70; 2014.
11. Kaplan N, Fowler X, Maqsoodi N, et al; Operative Anatomy of the Medial Gastrocnemius Recession vs the Proximal Medial Gastrocnemius Recession; *Foot Ankle Intl*; 38(4): 424-429. 2017.
12. Kiewiet N, Holthusen SM, Bohay DR, Anderson JG; Gastrocnemius Recession for Chronic Noninsertional Achilles Tendinopathy; *Foot Ankle Intl*; 34(4) 481- 485; 2013.
13. Maskill JD, Bohay DR, Anderson JG; Gastrocnemius Recession to Treat Isolated Foot Pain; *Foot and Ankle International* 31(1): 19-23, January 2010.
14. Molund M, Lapinskas SR, Nilsen FA, Hvaal KH; Clinical and Functional Outcomes of Gastrocnemius Recession for Chronic Achilles Tendinopathy; *Foot Ankle Intl*; 37(10):1091- 1097; 2016.
15. Morales-Munoz P, De Los santos Real R, Barrio Sanz P, et al; Proximal Gastrocnemius release in the treatment of Mechanical Metatarsalgia; *Foot Ankle Intl*; 37(7):782-789; 2016.



16. Pinney SJ, Hansen ST, Sangeorzan BJ; The Effect on Ankle Dorsiflexion of Gastrocnemius Recession; *Foot Ankle Intl*; 23(1): 26 – 29; 2002.
17. Sammarco GJ, Bagwe MR, Sammarco VJ, Magur EG; The Effects of Unilateral Gastrosoleus Recession; *Foot Ankle Intl*; 27(7): 508-511; 2006.
18. Silfverskiold N; Reduction of the Uncrossed Two- Joint muscles of the leg to one joint muscles in spastic conditions; *Acta Chir Scand*; 56: 315-328, 1924.
19. Strayer LM; Recession of the Gastrocnemius; *J Bone Joint Surg.* 32A: 671-676, 1950.
20. Strayer LM; Recession of the Gastrocnemius; five year report of cases. *J Bone Joint Surg.* 40A: 1019 – 1030, 1958.
21. Tashjian RZ, Appel AJ, Banerjee R, DiGiovanni CW; Anatomic Study of the Gastrocnemius-Soleus Junction and Its Relationship to the Sural Nerve; *Foot Ankle Intl*; 24(6): 473- 476: 2003.
22. Tashjian RZ, Appel AJ, Banerjee R, DiGiovanni CW; Endoscopic Gastrocnemius Recession: Evaluation in a Cadaver Model; *Foot Ankle Intl*;24(8): 607- 613; 2003.
23. Tellisi N, Elliott AJ; Gastrocnemius Aponeurosis Recession: A Modified Technique; *Foot Ankle Intl*; 29(12):1232-1234,2008.

Nextremity Solutions, Inc. funded this white paper.

For product information, including indications, contraindications, warnings, precautions, potential adverse effects and patient counseling information, see the package insert and [www.nextremitysolutions.com](http://www.nextremitysolutions.com).

Zimmer Biomet does not practice medicine. This document is intended for surgeons and is not intended for laypersons. Each surgeon should exercise his or her own independent judgment in the diagnosis and treatment of an individual patient, and this information does not purport to replace the comprehensive training surgeons have received. As with all surgical procedures, the technique used in each case will depend on the surgeon's medical judgment as the best treatment for each patient. Results will vary based on health, weight, activity and other variables. Not all patients are candidates for this product and/or procedure. Caution: Federal (USA) law restricts this device to sale by or on the order of a surgeon. Rx only.

PiroVue® is the trademark of Nextremity Solutions, Inc. Nextremity Solutions, Inc. is the legal manufacturer while Zimmer Biomet is the exclusive distributor.

©2018

LIT-1555