

Clinical Applications of the F3[®] Fragment Plating System in the Upper Extremity: A Series of Case Examples

Author: David M. Huebner, M.D.* and Susan G. Capps, Ph.D.†

Introduction

Plating of the small bones of the upper extremity requires reduction of the bone fragments, rigidfixation, and strength.^{1,2} These attributes are necessary for early active and passive range of motion following open reduction and internal fixation (ORIF) as stiffness is often a significant post-operative challenge to rehabilitation. Since the upper extremity often has a paucity of soft tissue coverage, low profile implants are advantageous. Finally, adaptability to the varied anatomy encountered in upper extremity fractures is a desirable attribute that allows for fixation in multiple scenarios without the need to maintain a large stock of devices and instruments.

The array of plates available with the F3[®] Fragment Plating System (Biomet, Inc/Hand Innovations, Miami, FL, USA) meets the needs described above. There are two basic types of plates, High-Flex and High-Strength (Figure 1). Each type is designed with a locking screw technology (non-locking screws are available), thus providing stable reconstruction in poor bone. Each plate hole has Fixed Angle Screw Targeting guides (F.A.S.T. Guide™ inserts), facilitating drilling and providing leverage points for in situ bending of the plates. Both the High Flex and High Strength plates can be contoured and bent in the axial and coronal planes (Figure 2), and the High Flex plate can also be bent in the sagittal plane (Figure 3). These plates may be initially fastened to the bone, and then contoured, or may be pre-bent to match the contour of a given patient's local anatomy. Plate cutters can easily trim the High Strength and the High Flex plates, although the benders can also be used to bend the High Flex plate up and down until it breaks.

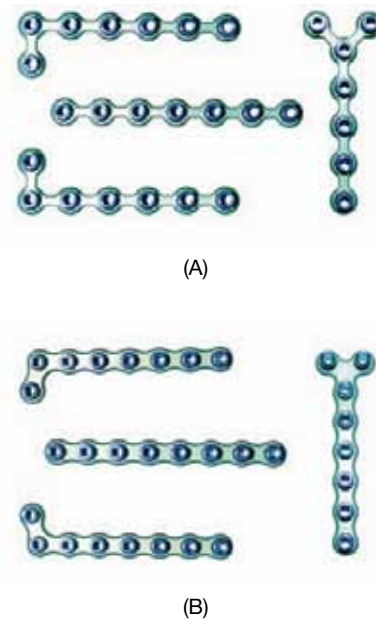


Fig. 1
F3[®] Plating System – (a) High-Flex Plate and (b) High-Strength Plate.

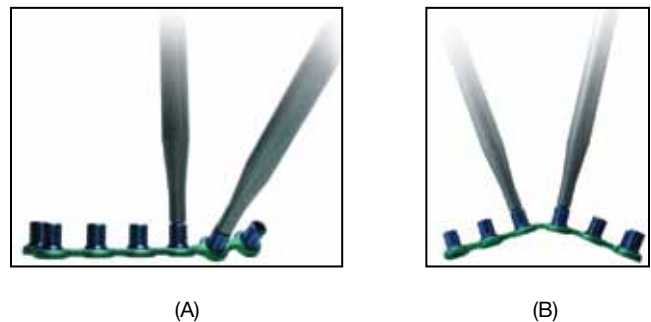


Fig. 2
F3[®] Plating System – (a) bending in the axial plane and (b) bending in the coronal plane.



Fig. 3
F3® Plating System, High-Flex Plate – bending in the sagittal plane.

Case Examples:

Distal Radius

While the vast majority of distal radius fractures requiring ORIF are amenable to fixed-angle locked plating, a minority benefit from “fragment specific” plates. Dorsal lip fractures with an intact volar cortex, radial styloid fractures, or very distal volar lip fractures are some examples of such fractures. The F3® plates can be successfully employed here due to their strength, low profile, adaptability, and locked screw fixation. Though dorsal fixation of distal radius fractures can be complicated by tendon irritation, the very low profile of the F3® plates allows the surgeon to easily close the extensor retinaculum over the plate to minimize the risk of this occurrence. The adaptability of the F3® plates allows the plates to be customized to the patient’s anatomy and to be placed very distal so that the screws are implanted into optimal subchondral bone (Figure 4). The strength of this plating construct and the locking screws may allow early active and passive range of motion after ORIF to minimize stiffness.

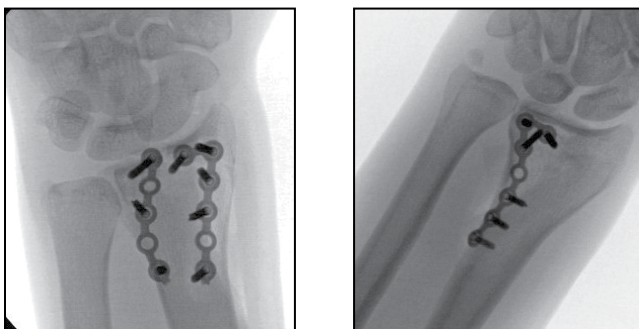


Fig. 4
Distal Radius Applications. On left: very distal dorsal lip fracture with intact volar cortex; low-profile F3® plating provided better fixation than supporting the fragment with a volar plate. On right: very distal volar lip fracture on ulnar side; F3® plating allows for more distal fixation than achievable with a standard volar locking plate.

Distal Ulna

Distal ulna fractures, whether isolated or in combination with distal radius fractures, can often benefit from ORIF. The most significant advantage of the F3® plates in distal ulna fractures is the low profile of the plating platform. As there is almost no soft tissue “padding” over the distal ulna, ORIF with more bulky plates often results in the need for hardware removal after the fracture is healed due to patient discomfort. A low profile, locking plate used in this context offers sufficient strength, which may allow early range of motion while minimizing hardware issues. In addition, the T- or L-shaped plates allow additional screws to be placed in a short distal fracture fragment (Figure 5).




Fig. 5
Distal Ulna Application. Patient is a small teenager with little forearm musculature; F3® plates are very low-profile and have the strength and locking options allowing for adequate reconstruction.

Metacarpal

The challenges encountered in operative fixation of metacarpal fractures are similar in nature to distal ulna fractures. With a paucity of soft tissue “padding,” low profile implants are required in order to minimize the risk of tendon irritation and hardware related issues. Strong implants are even more important as early range of motion is absolutely critical to avoid stiffness and improve patient outcomes. Additionally, using the L or T-shaped plates, combined with the contourability of the plates allows the surgeon to maximize short-segment periarticular fixation. The locking technology also allows stable fixation with long unicortical locking screws near the joint to minimize the risk of intra-articular penetration or tendon irritation from screws prominent through the far cortex. Finally, the combination of five metacarpals, periarticular fractures on the proximal and distal ends, metacarpal shaft fractures, and varied patient anatomy lead to an overwhelming combination of plate shapes that may be needed to adequately fix this array of possible metacarpal fractures. Because of the unique adaptability of the F3® plates including the sagittal plane flexibility of the High-Flex plate, the small number of F3® plates included in the set can be adapted to fit the anatomy of a wide array of fractures the surgeon may encounter (Figure 6).

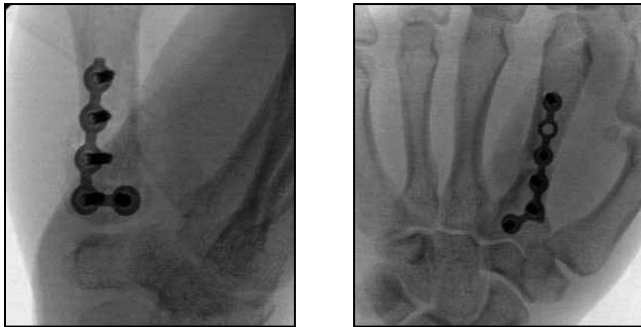

Fig. 6

Metacarpal Applications. The F3® plating system is ideal because it is a low-profile locking implant. The L-shaped bend and ability to contour allows for the maximum number of screws in the short peri-articular fragment.

Conclusions:

The F3® Fragment Plating System contains all of the desired attributes:

- High strength,
- Low profile, and
- High adaptability.

The F3® Fragment Plating System has demonstrated applicability for small fragment upper extremity fracture treatment with ORIF:

- Metacarpal,
- Distal radius,
- Distal ulna,

References

1. Bagby GW: Compression Bone-Plating—A Historical Perspective. J Bone Joint Surg AM 59(5): 625–631, 1997.
2. Jones WW: Biomechanics of Small Bone Fixation. Clin Orthop Rel Res (214): 11-18, 1987.
3. Hastings II H: Unstable Metacarpal and Phalangeal Fracture Treatment with Screws and Plates. Clin Orthop Rel Res (214): 37-52, 1987.
4. Orbay JL, Touhami A: Current Concepts in Volar Fixed-Angle Fixation of Unstable Distal Radius Fractures. Clin Orthop Rel Res (445): 58-67, 2006.
5. Freeland AE, Orbay JL: Extraarticular Hand Fractures in Adults. A Review of New Developments. Clin Orthop Rel Res (445): 133-145, 2006.

All trademarks herein are the property of Biomet, Inc. or its subsidiaries unless otherwise indicated.

This material is intended for the sole use and benefit of the Biomet sales force and physicians. It is not to be redistributed, duplicated or disclosed without the express written consent of Biomet.



One Surgeon. One Patient.®

P.O. Box 587, Warsaw, IN 46581-0587 • 800.348.9500 x 1501
©2012 Biomet Orthopedics • biomet.com
Form No. BMET0017.0 • REV060112