

# Zimmer Coonrad/Morrey Total Elbow

Surgical Technique



ZIMMER BIOMET  
Your progress. Our promise.™



# Table of Contents

- Indications/Contraindications** ..... 2
- Preoperative Considerations** ..... 3
- Surgical Technique** ..... 4
  - Incision ..... 4
  - Humeral Resection ..... 5
  - Preparation of the Ulna ..... 7
  - Trial Reduction ..... 9
  - Cement Technique ..... 9
  - Humeral Bone Graft ..... 10
  - Assembly and Impaction ..... 10
  - Closure ..... 11
- Postoperative Management** ..... 11

## INDICATIONS & CONTRAINDICATIONS

Indications include: post-traumatic lesions or bone loss contributing to elbow instability; ankylosed joints, especially in cases of bilateral ankylosis from causes other than sepsis; advanced rheumatoid or degenerative arthritis with incapacitating pain; revision arthroplasty; and instability or loss of motion when the degree of joint damage precludes less radical procedures.

The candidate for total elbow arthroplasty should exhibit joint destruction which significantly compromises the activities of daily living. Patients with single joint involvement (generally those with traumatic or degenerative arthritis) or significant lower extremity disability which require walking aids are less amenable to treatment than patients with advanced and predominately upper extremity involvement. If possible, elbow replacement should be done after hip or knee surgery to avoid excessive stress to the prosthesis required by crutch walking during total hip or knee rehabilitation.

Prior infection, paralysis, joint neuropathy, significant hand dysfunction, or excessive scarring of the skin which could prevent adequate soft tissue coverage are each distinct contraindications.

Use of the Coonrad/Morrey Total Elbow should not be considered for patients whose activities would subject the device to significant stress (i.e., heavy labor, torsional stress, or competitive sports).

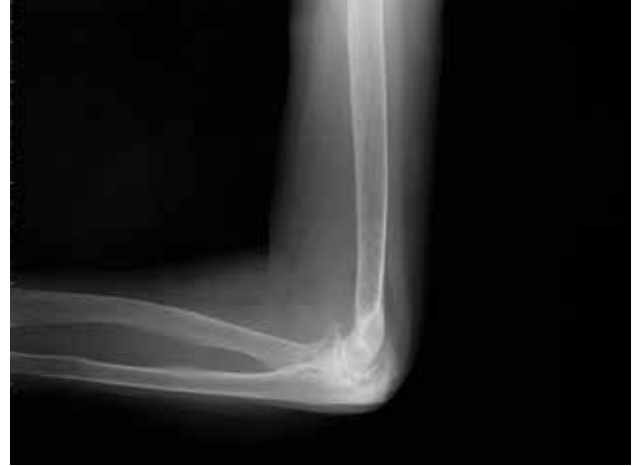Additionally, distant foci of infection, such as genitourinary, pulmonary, skin (chronic lesions or ulcerations), or other sites, are relative contraindications because hematogenous dissemination to the implant site may occur. The foci of infection should be treated prior to, during, and after implantation.

Joints that are neuropathic because of diabetes or other disease involving peripheral neuropathy are relative contraindications to total elbow arthroplasty.

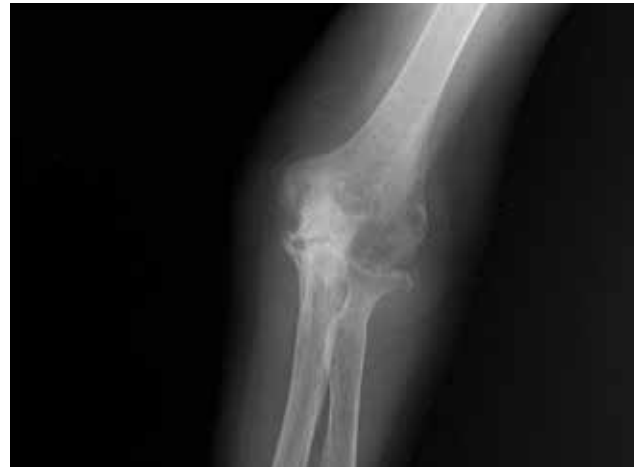## Preoperative Considerations

For those inexperienced in the technique of elbow arthroplasty, a trial with a fresh amputated, or cadaver specimen, is recommended. The surgeon should be aware of the coupling mechanism and the technique of articulating and disarticulating the two stems at the hinge joint. Attention should also be given to the need for bone grafting beneath the anterior flange. The insertion of a bone graft anteriorly enhances thickening of the bone stock at the point where maximum stress has been found to occur. The flange and bone graft were designed to resist torsional and posteriorly directed forces associated with loosening of the constrained implants.

In those patients having both shoulder and elbow pathology, the most severely involved joint should be done first. In patients with a pre-existing or anticipated ipsilateral shoulder replacement, the four-inch implant is to be used. A bone-graft plug is inserted in the canal at a depth of approximately 4.5 inches. At least 3 cm distance between the cement of the shoulder and elbow components is desirable.



Lateral View



Anterior/Posterior View

## Surgical Technique

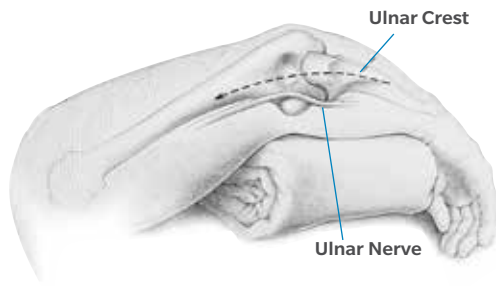


Figure 1

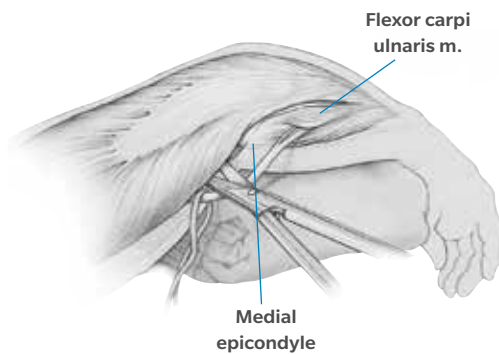


Figure 2

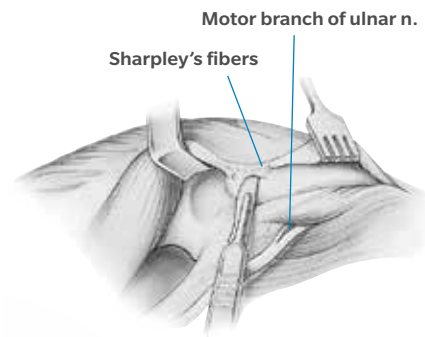


Figure 3

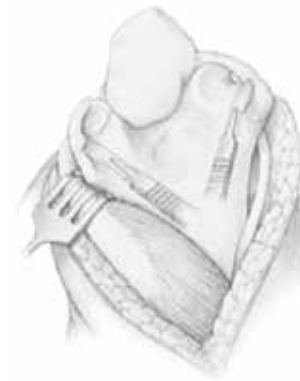

Figure 4

## Incision

Position the patient according to preference. The recommended position is supine with a sandbag under the scapula and the arm placed across the chest. Make a straight incision approximately 15 cm in length and centered just lateral to the medial epicondyle and just medial to the tip of the olecranon (Figure 1).

Identify the medial aspect of the triceps mechanism and isolate the ulnar nerve using ocular magnification and a bipolar cautery. Mobilize the ulnar nerve to the first motor branch and very carefully translocate it anteriorly into the subcutaneous tissue (Figure 2). The nerve must be protected throughout the remainder of the procedure.

Make an incision over the medial aspect of the ulna and elevate the ulnar periosteum along with the forearm fascia (Figure 3). Then retract the medial aspect of the triceps along with the posterior capsule. Remove the triceps from the proximal ulna by releasing Sharpey's fibers from their insertion. Further reflect the extensor mechanism laterally including the anconeus, allowing complete exposure of the distal humerus, proximal ulna, and the radial head (Figure 4). Sublux the entire extensor mechanism laterally.

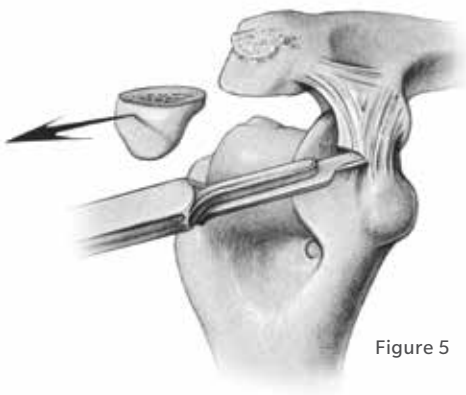


Figure 5

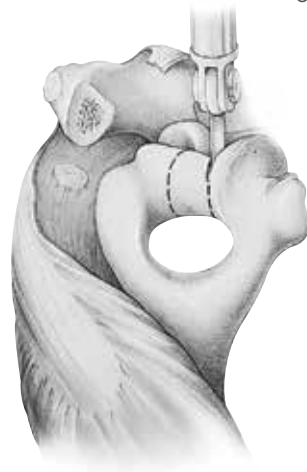


Figure 7

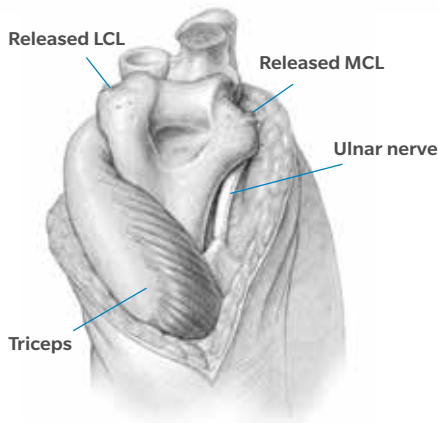


Figure 6

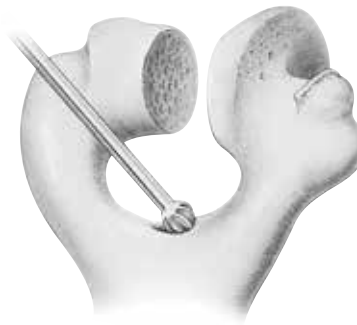


Figure 8

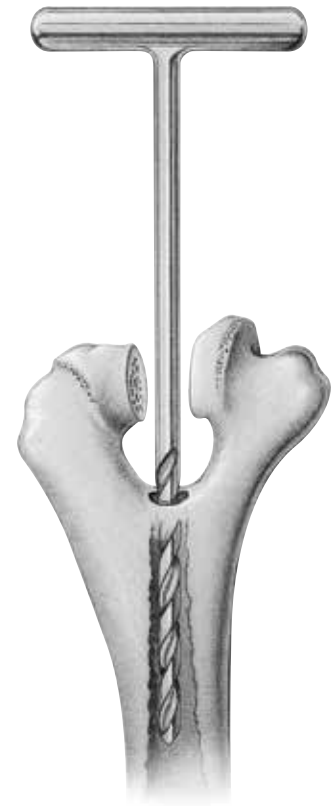


Figure 9

## Incision (cont.)

Remove the tip of the olecranon and release the medial and lateral collateral ligaments from their humeral attachment (Figure 5). Flex the elbow to separate the distal articulation from the humerus (Figure 6). Externally rotate the forearm to allow further flexion and separation of the articulation.

## Humeral Resection

Remove the mid-portion of the trochlea with a rongeur or saw (Figure 7) to facilitate access to the medullary canal of the humerus.

Identify the canal by removing a small portion of cortical bone from the roof of the olecranon fossa with a burr or rongeur (Figure 8). Then enter the medullary canal with the Awl Reamer (Figure 9). Identify the medial and lateral aspects of the supracondylar columns, and visualize them throughout the preparation of the distal humerus to assure proper alignment and orientation.

Attach the T-handle to the Humeral Alignment Guide and insert the guide into the humeral canal.

Attach the side arm to the radial side of the selected size Humeral Cutting Guide so the “Right” or “Left” indication on the side arm is adjacent to the “Right” or “Left” indication on the cutting guide. Tighten the knurled knob.

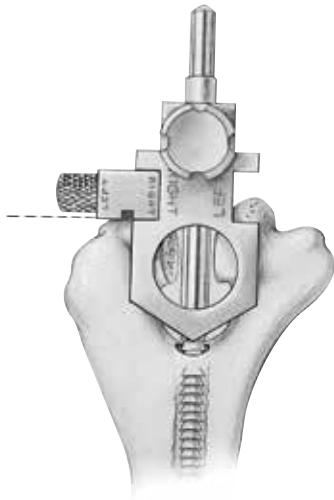


Figure 10

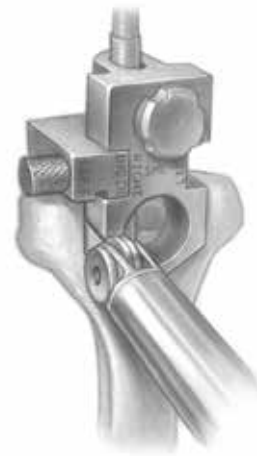


Figure 12

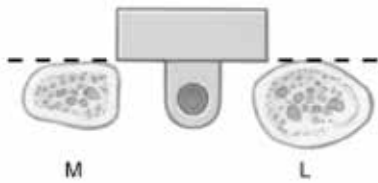


Figure 11

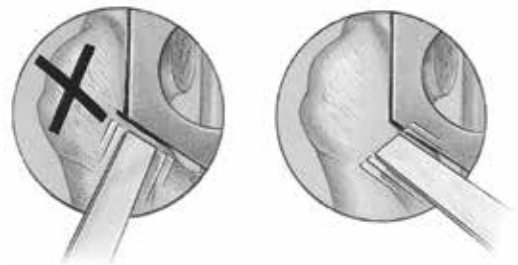


Figure 13

## Humeral Resection (cont.)

Remove the T-handle from the alignment guide and slide the cutting guide onto the posterior side of the alignment guide. The arm should rest on the capitellum in order to provide the appropriate depth of cut (Figure 10).

Use the plane formed by the posterior cortices of the medial and lateral columns to determine the rotational orientation of the humeral resection (Figure 11). The cutting guide should be parallel to this plane. When the cutting guide is properly aligned, tighten the thumb screw.

The width of the Humeral Cutting Guide corresponds to the selected size humeral component, and allows accurate removal of the articular surface of the distal humerus. Use an oscillating saw to remove only the remaining trochlea by cutting first along the medial and lateral planes of the cutting guide (Figure 12), and then along the proximal planes. Be careful to avoid violating either supracondylar bony column as this may cause a stress riser that can result in fracture of this structure (Figure 13). The proximal cut usually leaves the cortical bone intact on either side of the guide. If preferred, remove the cutting guide and the alignment guide to finish the resection down to the roof of the olecranon fossa. Then remove the fragments. If desired, inserting the distal end of the appropriate size Humeral Provisional between the bony columns can check the accuracy of the cut.



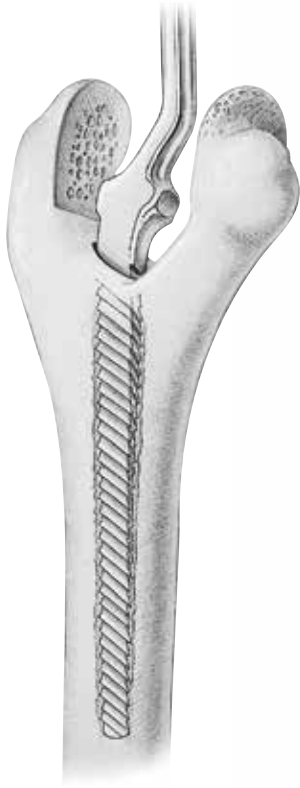

Figure 14

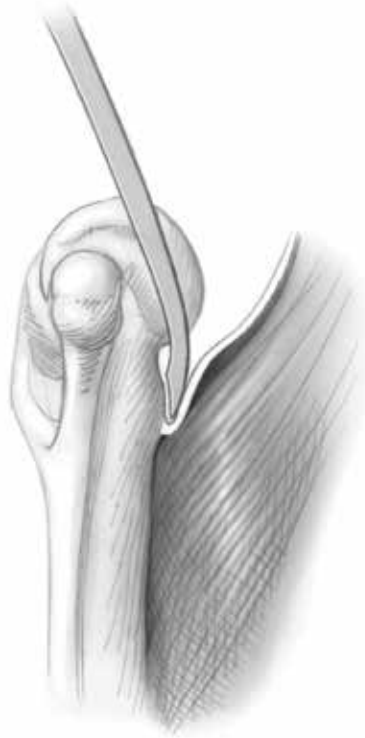

Figure 15

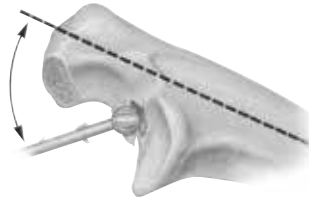


Figure 16

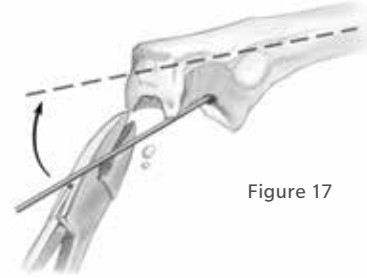


Figure 17

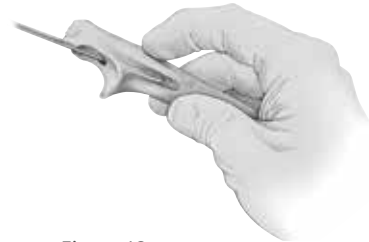

Figure 18

## Humeral Resection (cont.)

Begin rasping the humeral canal with the Starter Rasp. If necessary, gently twist the rasp to further open the canal. Then use the Humeral Rasp that corresponds to the selected size humeral component (Figure 14). If implanting the extra-small sized humeral component, only the starter rasp is to be used (moderate burring of the distal section of the canal may be required to assure trial and implant fit). This results in a final opening in the roof of the olecranon fossa that is smaller than that of the diameter of the medullary canal.

To prepare a position for the humeral flange and bone graft, release the anterior capsule from the anterior aspect of the distal humerus and use a 12mm-20mm curved osteotome to elevate the brachialis muscle (Figure 15).

## Preparation of the Ulna

Identify the medullary canal of the ulna by using a high-speed burr to remove the subchondral bone at the base of the coronoid (Figure 16). If necessary, remove more bone from the tip of the olecranon or “notch” it to allow the incrementally sized Starter Awls to be introduced axially down the medullary canal (Figure 17). Use the Starter Awls with a twisting motion to further identify and widen the canal. Place a finger over the exposed proximal shaft of the ulna to help prevent violation of the medullary canal (Figure 18).

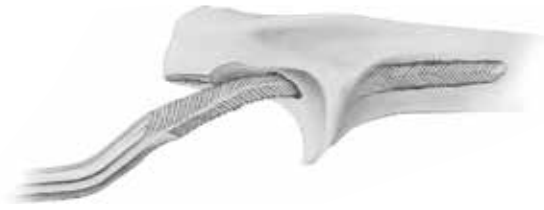

Figure 19

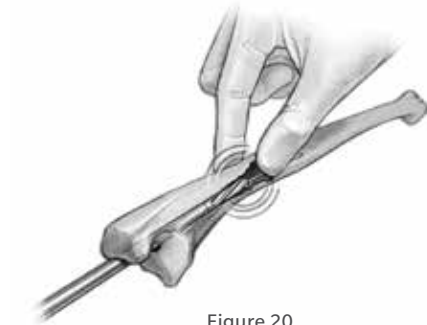

Figure 20

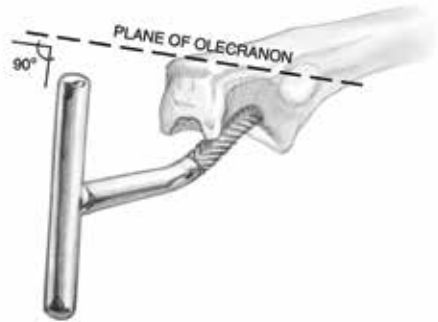


Figure 21

### Preparation of the Ulna (cont.)

Use the Pilot Rasp to further open the canal. Then use the right or left Starter Rasp. If implanting the extra-small ulnar component, the Starter Rasp is the final rasp, and must be fully seated in order to allow proper depth of insertion of the extra-small implant (this may require removal of additional intramedullary bone stock proximally using a Steinmann pin or similar instrument). If implanting a small or regular ulnar component, use a gentle twisting motion to insert the Small or Regular Rasp in the appropriate right or left configuration (Figure 19). If implanting a small component and the canal is large enough, follow the Small Rasp with the Regular Rasp to provide a greater cement mantle around the implant.

To prepare the last several millimeters of the ulnar canal, use a mallet to remove the subchondral bone around the coronoid and the medullary canal. If desired, and the canal is small, flexible reamers can be used to prepare the canal (Figure 20). Determine the final orientation of the implant by placing the rasp down the canal with the handle perpendicular to the “flat” of the olecranon (Figure 21).

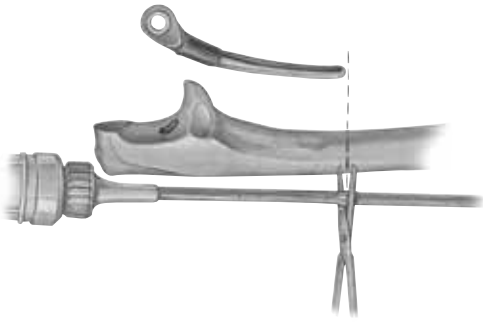


Figure 22

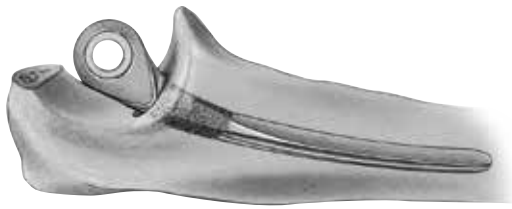

Figure 23

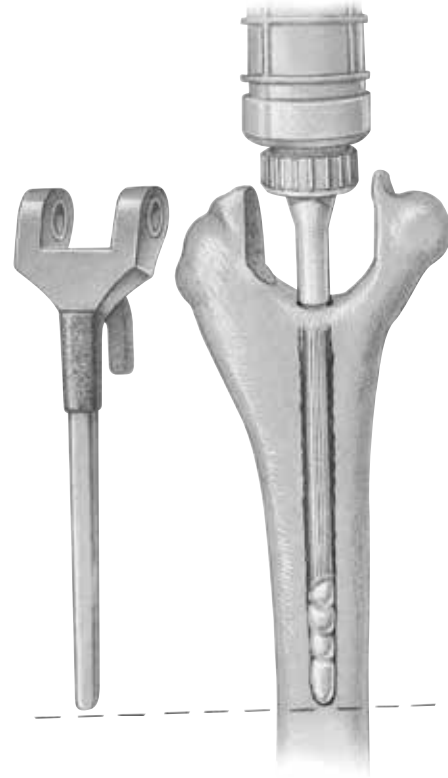


Figure 24

## Trial Reduction

Insert the appropriate size ulnar and humeral provisionals. Articulate the two provisionals, and connect them by placing the pin provisional across the two components. After the provisional prosthesis has been coupled, perform a trial reduction and range of motion. Then remove the provisional components.

## Cement Technique

Using a pulsating lavage irrigation system, thoroughly clean and dry the medullary cavities of both bones. Inject cement down the medullary canal of the ulna, or both the ulna and humerus, with a delivery system designed to fit down even the smallest ulnar canal. Cut the flexible tubing to the appropriate length for either the humeral or ulnar component (Figure 22). Because of high resistance, inject the cement early in the polymerization process.

Insert the ulnar component first as far distally as the coronoid process. The center of the ulnar component should align with the projected center of the greater sigmoid notch (Figure 23). The flat of the ulnar component should be parallel to the flat of the olecranon.

After the cement has hardened and excess has been removed from around the ulnar component, follow an identical process for injecting the cement in the humeral canal. Remember that the humeral orifice is smaller than the medullary canal. Use a specially designed plug or pieces of bone graft to provide cement retention when indicated. Cut the injection tubing to the appropriate length and inject the cement down the medullary canal in a routine fashion (Figure 24).



Figure 25

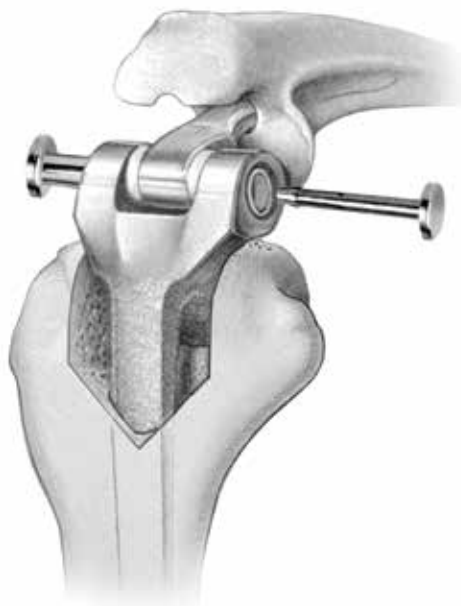


Figure 26

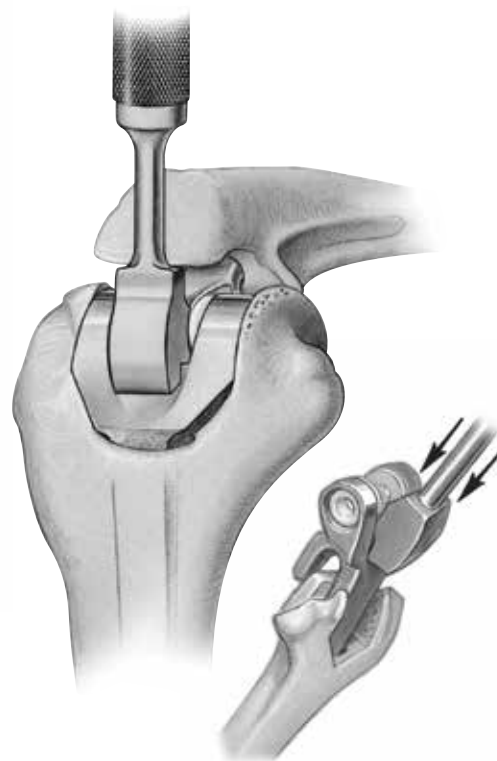


Figure 27

## Humeral Bone Graft

Prepare a bone graft from the excised trochlea, or from the iliac crest or bone bank for revision surgery. The graft should measure about 2mm to 3mm in thickness and be about 1.5 cm in length and 1 cm in width. Place approximately one-half of the bone graft anterior to the anterior cortex of the distal humerus, and expose the other half through the resected trochlea. Insert the humeral component down the canal to a point that allows articulation of the device. At this position the bone graft is “captured” by the flange (Figure 25).

## Assembly and Impaction

Articulate the ulnar and humeral components, and connect them by placing the hollow, outer axis pin across the two components and securing it with the solid internal axis pin (Figure 26). Be sure that the two pins are fully engaged. A click should be heard and felt when the two pins are connected. If not, soft tissue is likely trapped between the pin and the implant preventing complete engagement. After the prosthesis has been coupled, use the Humeral Impactor to impact the humeral component down the medullary canal (Figure 27). Typically, the component should be inserted so that the axis of rotation of the prosthesis is at the level of the normal anatomic axis of rotation. This is approximately where the base of the flange is flush with the anterior bone of the coronoid fossa. Flex and extend the elbow to identify areas of impingement, and remove any impinging bone with a rongeur.

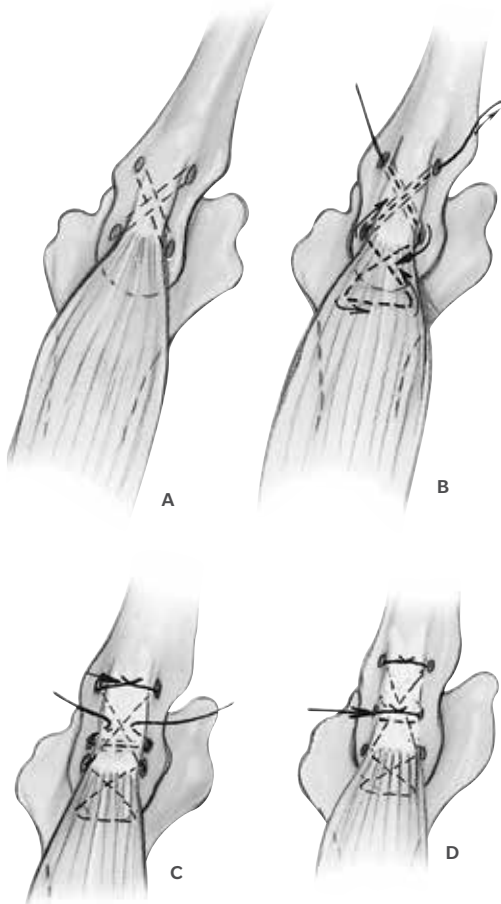


Figure 28

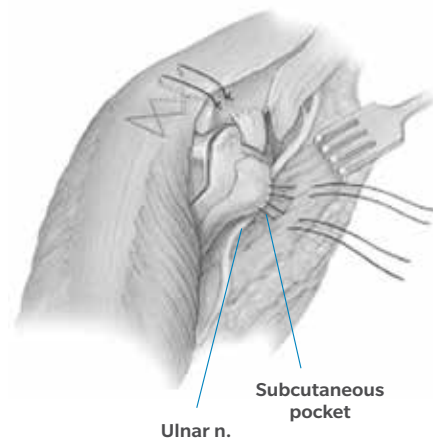
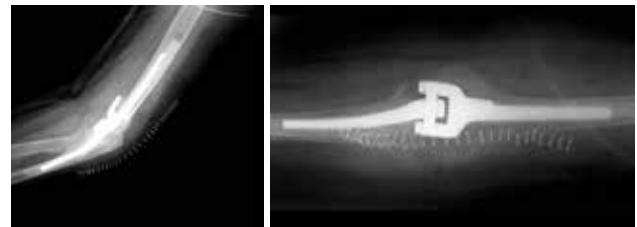


Figure 29



Lateral View

Anterior/Posterior  
View

## Closure

Deflate the tourniquet and obtain hemostasis. Insert a drain, if desired, and close the wound in layers. Return the triceps mechanism to its anatomic position and secure it with sutures placed through cruciate and transverse drill holes in the proximal ulna. Place a heavy #5 nonabsorbable suture in a crisscross fashion in the triceps, and a second suture in a transverse manner. Tie these sutures with the elbow flexed at 90 degrees (Figure 28). To protect the ulnar nerve, place it in a subcutaneous pocket (Figure 29). There is no need to repair the collateral ligaments. Use absorbable sutures to repair the remaining portion of the triceps mechanism. Then complete the closure in a routine fashion. Apply a compressive dressing with the elbow in full extension.

## Postoperative Management

Elevate the arm postoperatively for two to four days with the elbow above shoulder level. Remove the drains, if used, at approximately 24 to 36 hours, and the compressive dressing on the second day after surgery. Apply a light dressing and allow elbow flexion and extension as tolerated. Use a collar and cuff, and instruct the patient on activities of daily living. Typically, no formal physical therapy is required or indicated unless necessary for the shoulder or hand. Avoid strengthening exercises. The patient should be advised not to lift more than one pound during the first three postoperative months and not lift more than five pounds with the operated arm.

For indications, contraindications, warnings, precautions, potential adverse effects and patient counselling information, see the package insert or contact your local representative; visit [www.zimmerbiomet.com](http://www.zimmerbiomet.com) for additional product information. Zimmer Biomet does not practice medicine. This technique was developed in conjunction with health care professionals. This document is intended for surgeons and is not intended for laypersons. Each surgeon should exercise his or her own independent judgment in the diagnosis and treatment of an individual patient, and this information does not purport to replace the comprehensive training surgeons have received. As with all surgical procedures, the technique used in each case will depend on the surgeon's medical judgment as the best treatment for each patient. Results will vary based on health, weight, activity and other variables. Not all patients are candidates for this product and/or procedure. Caution: Federal (USA) law restricts this device to sale by or on the order of a surgeon. Rx only.

All content herein is protected by copyright, trademarks and other intellectual property rights, as applicable, owned by or licensed to Zimmer Biomet or its affiliates unless otherwise indicated, and must not be redistributed, duplicated or disclosed, in whole or in part, without the express written consent of Zimmer Biomet.

This material is intended for health care professionals. Distribution to any other recipient is prohibited.

© 2021 Zimmer Biomet



**ZIMMER BIOMET**

Your progress. Our promise.™



**Legal Manufacturer**  
Zimmer, Inc.  
1800 West Center Street  
Warsaw, Indiana 46580  
USA

[zimmerbiomet.com](http://zimmerbiomet.com)

**CE** 2797