

DeNovo[®] NT Natural Tissue Graft

Arthroscopically-Assisted Surgical Technique
for Ankle Cartilage Repair

Surgical Technique

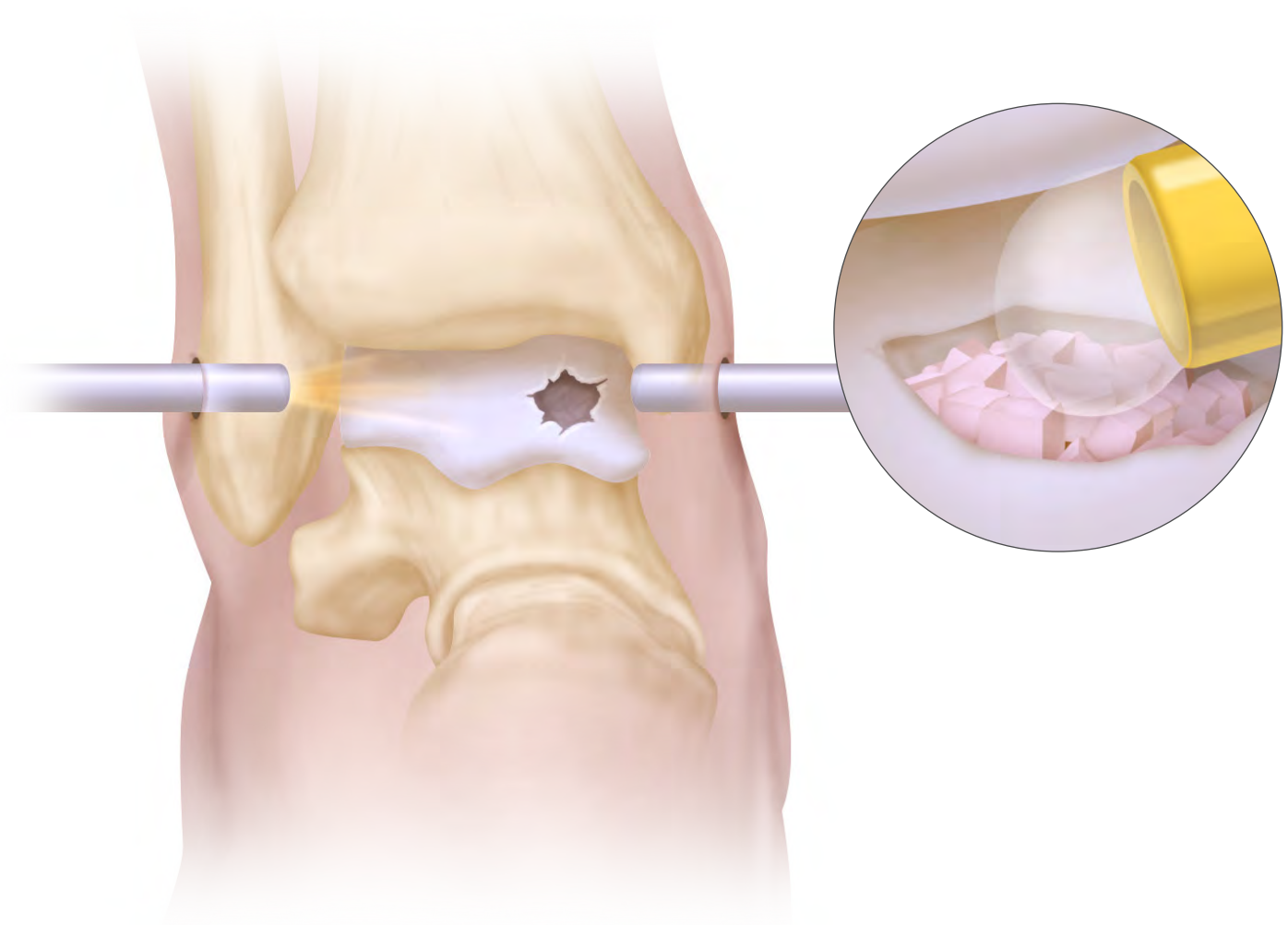
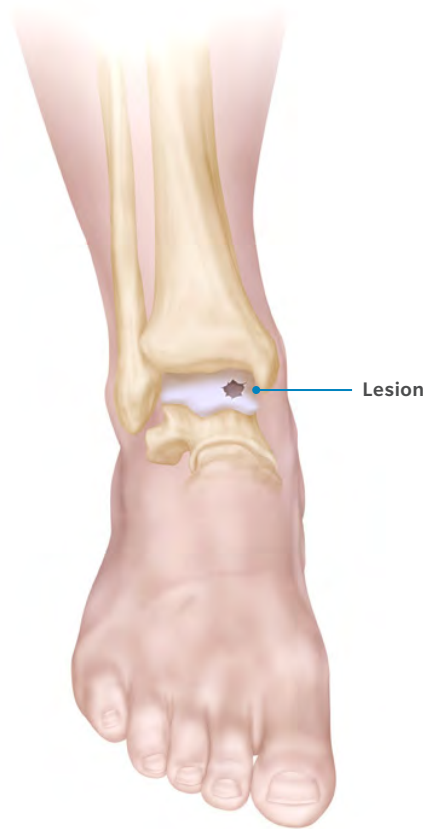


Table of Contents

- Overview 2
- Pre-operative Planning 2
- Ligament Preparation and Bony Alignment 2
- Patient Preparation 3
- Fibrin Preparation 3
- Arthroscopy 3
- Prepare the Cartilage Lesion 4
- Create a Viable Bone Bed 4
- Dry the Lesion and Create an “Extended Portal” Incision 5
- Preparation DeNovo NT Graft 5
- Load DeNovo NT Graft into a Delivery Cannula 6
- Cover Lesion Base with Fibrin 6
- Deliver DeNovo NT Graft 7
- Set and Test 8
- Final Inspection and Close 8
- Post-operative Care 9



Overview

DeNovo NT Natural Tissue Graft is an off-the-shelf human tissue allograft, consisting of juvenile hyaline cartilage pieces with viable chondrocytes, and is intended for the repair of articular cartilage lesions in a single-stage procedure. The DeNovo NT Graft surgical technique eliminates the need for harvesting and suturing of a periosteal flap, as it employs fibrin to secure the particulated tissue pieces into the lesion.

DeNovo NT Graft is an alternative to other cartilage treatment options in the ankle, where it is often used as a primary treatment option for lesions larger than 1 cm² or as a secondary treatment option to previous cartilage repair treatments that have failed.

Pre-operative Planning

Pre-operative planning may include an MRI or CT scan to better estimate the size and location of the cartilage lesion. One pack of tissue graft is recommended to treat each 2.5 cm² of lesion surface area, with a recommended fill ratio of at least 50 percent of the lesion size.

Ligament Preparation and Bony Alignment

Ligament laxity should be addressed at the time of DeNovo NT grafting to ensure stable and natural joint mechanics; consider performing a lateral or medial ligament reconstruction. Do not tie sutures until the DeNovo NT Graft is in place. Axial deformity should be corrected with a calcaneal or tibial osteotomy to achieve normal operative joint alignment.

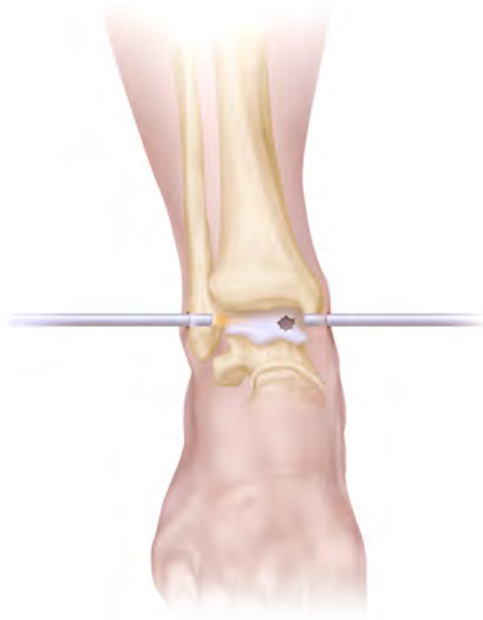

Figure 1
External view of the arthroscope and internal arthroscopic view of lesion.

Patient Preparation

Standard methods of joint distraction may facilitate visualization of the lesion and access to the lesion for treatment. These include traction, a weighted ankle wrap, etc. A space of 4-5 mm within the joint is suggested to prepare the lesion and deliver the graft.

Fibrin Preparation

DeNovo NT Graft, a minimally manipulated juvenile allograft cartilage tissue, is intended for the treatment of focal cartilage lesions and requires the use of a fibrin preparation to secure the cartilage graft into place. Autologous fibrin is recommended to achieve DeNovo NT Graft fixation (fibrin preparation instructions may be obtained from Zimmer Biomet or from your local blood bank). Be sure the fibrin is ready to implant prior to initiating filling of the lesion. The availability of 2-3 fibrin delivery tips is recommended since the tips may become obstructed as the fibrin cures.

Arthroscopy

Perform a diagnostic arthroscopy to visualize the ankle lesion using a 2.7 mm or 1.9 mm arthroscope to inspect the lesion (Figure 1). Removal of the distal tibial cortical bone anterior to the cartilage surface of the tibia (tibial plafondoplasty) may be performed as needed to obtain adequate visualization of posterior lesions.

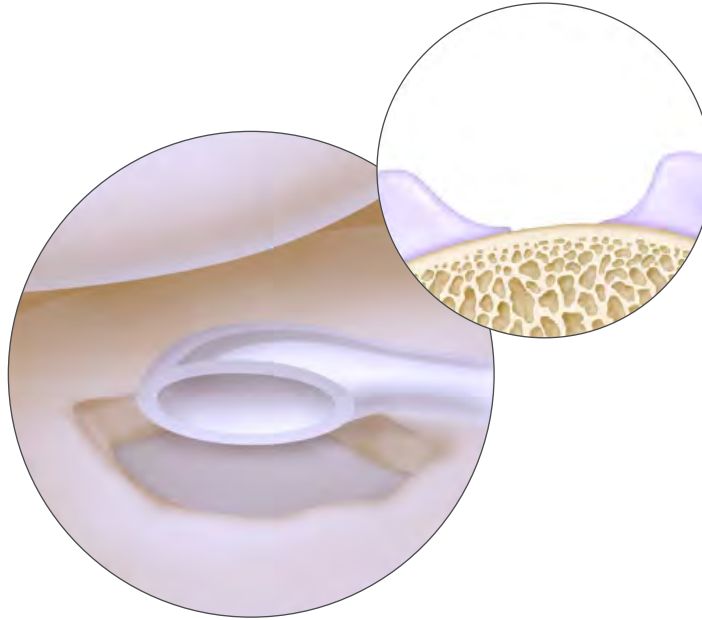


Figure 2
A stable, well-shouldered lesion with vertical walls.

Prepare the Cartilage Lesion

Curette the lesion to a stable border (margin), removing the affected cartilage down to the subchondral plate, including the calcified cartilage layer to ensure bone bed viability (Figure 2). It is suggested that at least 50-60% of the cartilage lesion be contained by a border of native cartilage tissue to maintain adequate post-operative graft fixation to and stability at the lesion site.

Probe the margin of the surrounding native cartilage to ensure that it is stable.

Irrigate and remove any cartilage debris or loose bodies.

Create a Viable Bone Bed

If the subchondral bone plate appears sclerotic, perform an appropriate procedure. Bone grafting may be done where necessary to achieve a healthy subchondral bone base and recipient site for the cartilage graft. Generally, it is advisable to restore the height of the subchondral bone bed for a bony lesion of >5 mm in depth from the bottom surface of adjacent healthy cartilage.

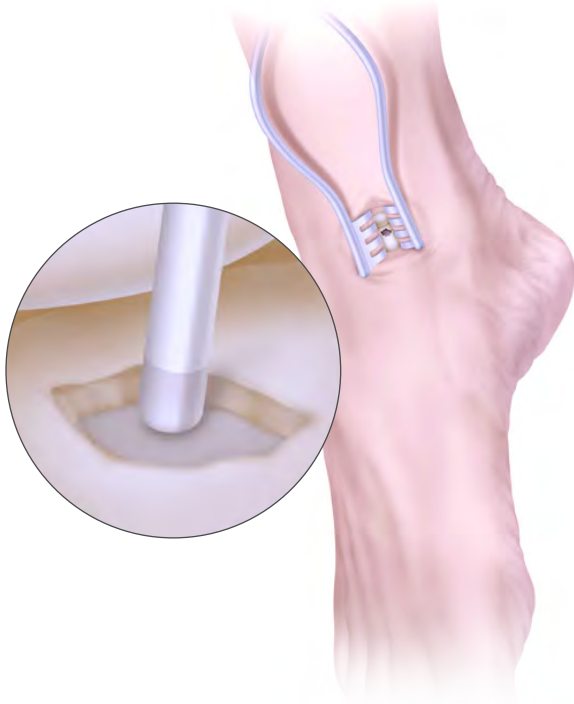

Figure 3

Clean and dry the lesion with an appropriate curved suction tube, gauze or pledgets, and place soft tissue retractors to provide visualization of the lesion.

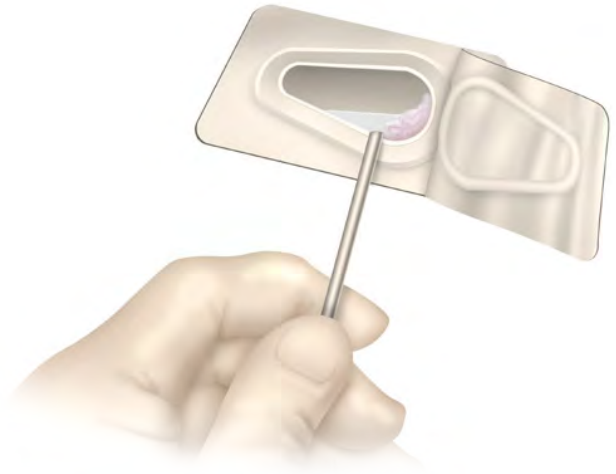


Figure 4

Siphon the fluid from the package with tissue remaining in the large end of the blister pack.

Dry the Lesion and Create an “Extended Portal” Incision

It is vital to deliver the DeNovo NT Graft and fibrin into a dry environment (whether under a “dry scope” or open arthrotomy procedure) to prevent the graft tissue from being washed away and to allow the fibrin to cure.

Turn off and remove the arthroscopic inflow. Apply traction as required to provide enough working joint space, and extend the portal incision by approximately 1-2 cm. Clean and dry the lesion with an appropriate curved suction tube, gauze or pledgets, and place retractors for direct visualization of the lesion site (Figure 3).

Technique Tip: A plafondoplasty may be performed if visualization of the lesion is still limited.

Prepare DeNovo NT Graft

Introduce the appropriate number of DeNovo NT Graft packages into the sterile field using standard aseptic technique (1 pack per 2.5 cm² of lesion surface area). Stand the package upright to allow cartilage pieces to fall to one end of the blister pack, return the package to a horizontal position and remove the foil covering. Aspirate the tissue preservation medium from the open package with a syringe, being careful not to aspirate any cartilage pieces (Figure 4).

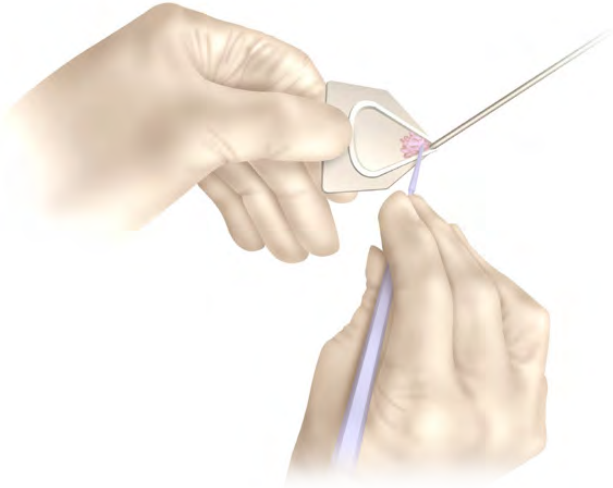


Figure 5

Using a Freer elevator or spatula, load DeNovo NT Graft cartilage pieces retrograde into a small cannula. Alternatively, slide the cannula across the bottom of the package and press against the blister pack sidewall to load DeNovo NT Graft pieces retrograde.

Load DeNovo NT Graft into a Delivery Cannula

To facilitate loading of the cartilage pieces into a delivery cannula, create a scooped funnel with the packaging by cutting off the small end of the blister packaging.

Using a Freer elevator or spatula, load DeNovo NT Graft cartilage pieces retrograde into a small cannula (e.g., a 1.9 mm arthroscopy outflow cannula with the accompanying obturator removed during loading) (Figure 5). Alternatively, slide the cannula across the bottom of the package and press against the blister pack sidewall to load DeNovo NT Graft pieces retrograde; this may also be done with pickups, one or two pieces at a time.

Insert a fitting plunger/obturator and push the loaded pieces toward the opening of the cannula, using a finger to guard the cannula opening at the opposite end to prevent premature expulsion of the graft.

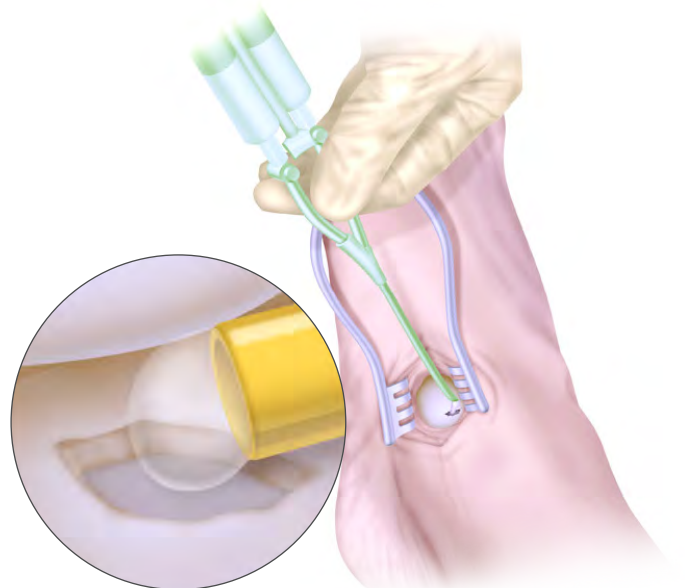


Figure 6

External view of the fibrin syringe inserted through the extended portal incision. Inset: Arthroscopic view of syringe tip in place and fibrin extruded into lesion bed.

Cover Lesion Base with Fibrin

Curve the tip of the fibrin applicator as needed, and ensure that there is enough room in the joint to prevent fibrin from adhering to the opposing tibial surface. With the tip pointing towards the lesion, carefully cover the base of the lesion with a small amount of fibrin (Figure 6).



Figure 7
Push tissue graft down the cannula and into the lesion bed.

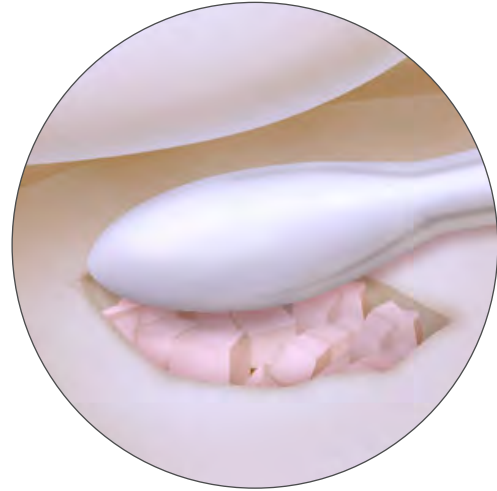

Figure 8
Spread the tissue graft evenly in the lesion bed and tamp into the fibrin bed.

Deliver DeNovo NT Graft

After about 1-2 minutes and before the fibrin fully cures, introduce the loaded cannula, and use the obturator to extrude the DeNovo NT Graft cartilage pieces into the lesion and on top of the fibrin (Figure 7). Ensure that at least 50% of the lesion area is covered with uniformly distributed tissue pieces. In areas that are not fully shouldered, it is recommended that a gap of approximately 1 mm be left between the tissue pieces and the edge of the lesion to minimize the risk of graft delamination.

While there is enough tissue in each unit/package of DeNovo NT Graft to treat a 2.5 cm² lesion (e.g., dimensions of 1.0 cm x 2.5 cm), one unit of tissue will actually cover approximately 50% (i.e., 1.25 cm²) of that surface area. The post-market clinical history to date supports that a tissue/fibrin construct having a 50% fill volume is sufficient for lesion repair.

Using a Freer elevator, carefully spread the tissue pieces evenly and tamp down to embed them into the fibrin. The technique is somewhat analogous to creating a mosaic tile, where the pieces of tissue are arranged evenly across the base of the defect at a minimum 50% fill, and the fibrin is used as the “grout” to hold the pieces of tissue together to form the tissue/fibrin construct (Figure 8).

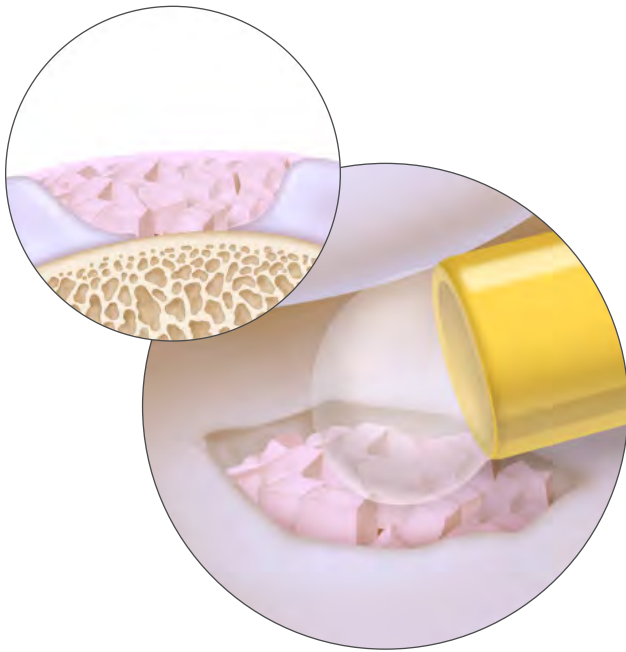


Figure 9

Apply additional fibrin glue to complete the tissue/fibrin construct. Ensure that final tissue/fibrin construct does not sit proud in the joint space.

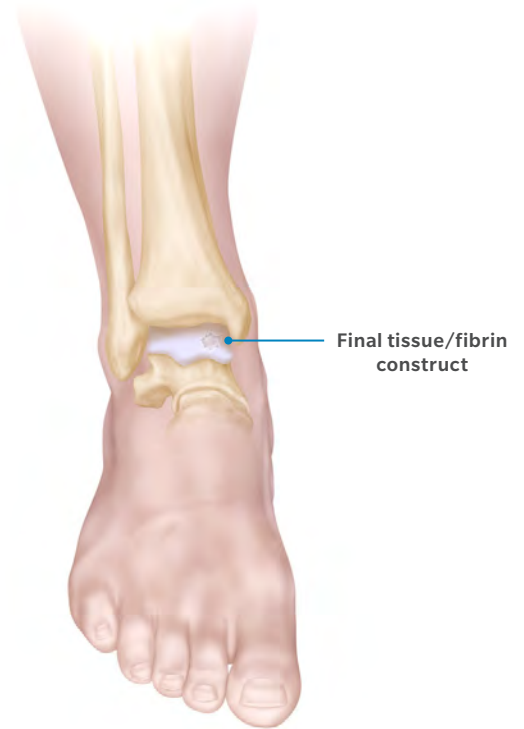

Figure 10

Completed lesion treatment and incision closure.

Set and Test

Allow DeNovo NT Graft to sit in the lesion for several minutes as the fibrin cures.

Apply an additional amount of fibrin to fully embed the cartilage tissue pieces, completing the tissue/fibrin construct (Figure 9). Be careful not to apply so much fibrin that the completed construct sits proud in the joint space. Additional cartilage and fibrin may be applied in similar fashion as the depth of the lesion permits. Allow at least an additional 3-4 minutes for the completed tissue/fibrin construct to fully cure.

Slowly dorsiflex/plantarflex the ankle to ensure that cartilage graft pieces are compressed down into the lesion and to help establish a contoured surface. Range the joint to ensure that the tissue graft does not impinge in the joint.

Final Inspection and Close

Check for any extraneous debris or dislodged cartilage pieces and remove with forceps or gentle suction. Perform a standard closure with suture, and apply a splint with the ankle in a neutral position (Figure 10).

Post-operative Care

General post-operative guidelines include:

- **Non-weight bearing for 6 weeks**
 - Weeks 0-2: Posterior plaster splint with the ankle in neutral position is used until sutures are removed
 - Weeks 2-6: A generic removable boot brace is used. Gentle active and passive range of motion exercises out of the brace are initiated to prevent contracture. Strengthening and elastic band resistance exercises are done, with limited plantar flexion (<20 degrees) to maintain graft containment. Consider use of a night splint depending on size and location of lesion.
- **Weight bearing with walking/protected activities 6-12 weeks**
 - Week 6: Advance to weight-bearing-as-tolerated in the brace, with increasing ROM exercises, bike, non-impact cardio and pool therapy.
 - Weeks 6-12: Wean from the brace.
- **More active rehabilitation 12-52 weeks**
 - Weeks 12-24: Encourage walking and a gradual increase in activity.
 - Weeks 24-52: Advance to running and loading activities.

This material is intended for health care professionals and the Zimmer Biomet sales force only. Distribution to any other recipient is prohibited. All content herein is protected by copyright, trademarks and other intellectual property rights owned by or licensed to Zimmer Biomet or its affiliates unless otherwise indicated. This material must not be redistributed, duplicated or disclosed, in whole or in part, without the express written consent of Zimmer Biomet.

Check for country product clearances and reference product specific instructions for use. For complete product information, including indications, contraindications, warnings, precautions, and potential adverse effects, see the package insert and Zimmer Biomet's website.

This technique was prepared in conjunction with a licensed health care professional. Zimmer Biomet does not practice medicine and does not recommend any particular orthopedic implant or surgical technique for use on a specific patient. The surgeon is responsible for determining the appropriate device(s) and technique(s) for each individual patient.

©2018 Zimmer Biomet



ZIMMER BIOMET

Your progress. Our promise.®