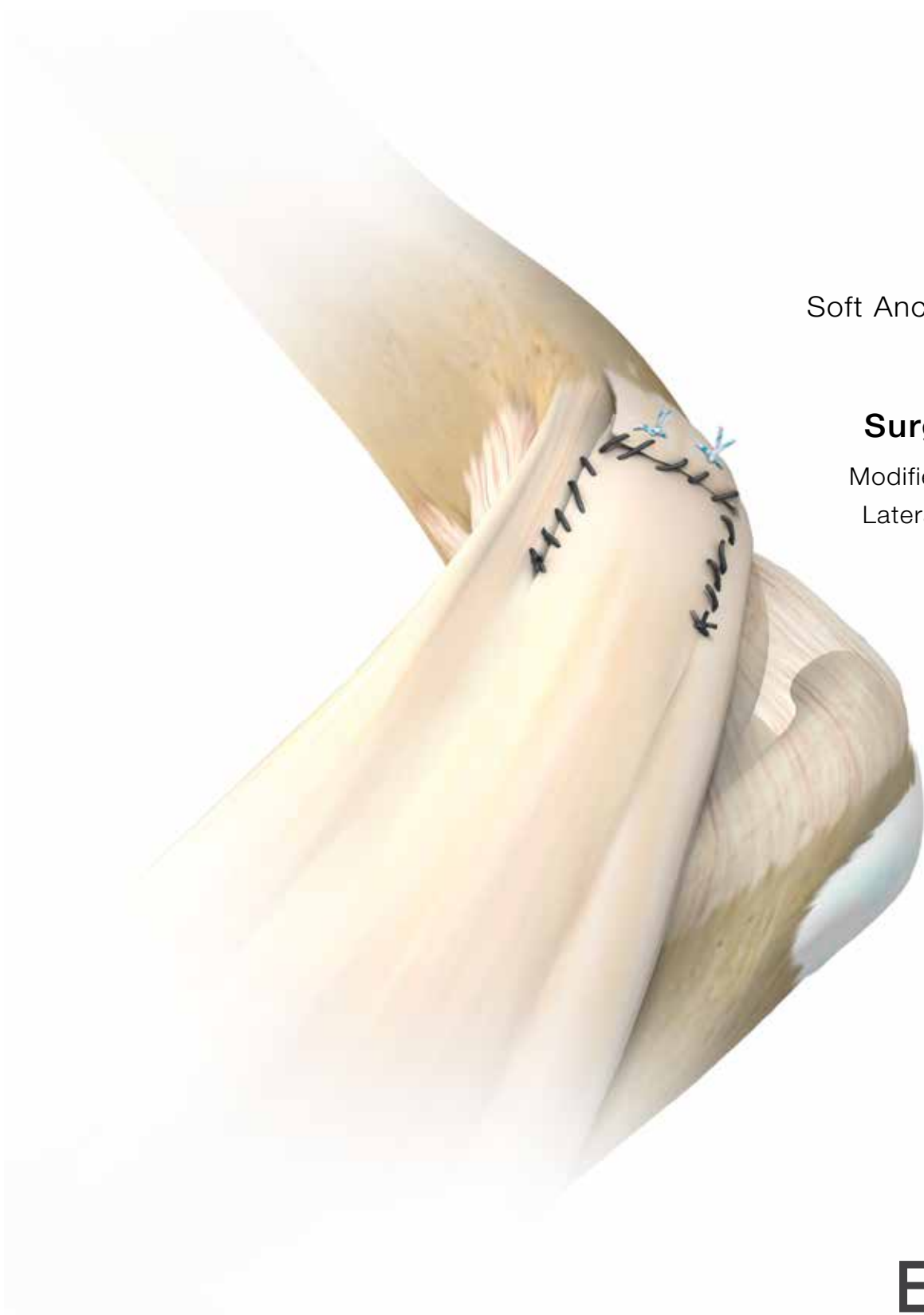

JuggerKnot

Soft Anchor – 1.4 mm Short

Surgical Technique

Modified Garden Procedure:
Lateral Epicondylitis Repair

Surgical Protocol by
Jeffrey Nacht, M.D.

BIOMET

One Surgeon. One Patient.

Over 1 million times per year, Biomet helps one surgeon provide personalized care to one patient.

The science and art of medical care is to provide the right solution for each individual patient. This requires clinical mastery, a human connection between the surgeon and the patient, and the right tools for each situation.

At Biomet, we strive to view our work through the eyes of one surgeon and one patient. We treat every solution we provide as if it's meant for a family member.

Our approach to innovation creates real solutions that assist each surgeon in the delivery of durable personalized care to each patient, whether that solution requires a minimally invasive surgical technique, advanced biomaterials or a patient-matched implant.

When one surgeon connects with one patient to provide personalized care, the promise of medicine is fulfilled.

JuggerKnot Soft Anchor–1.4 mm Short

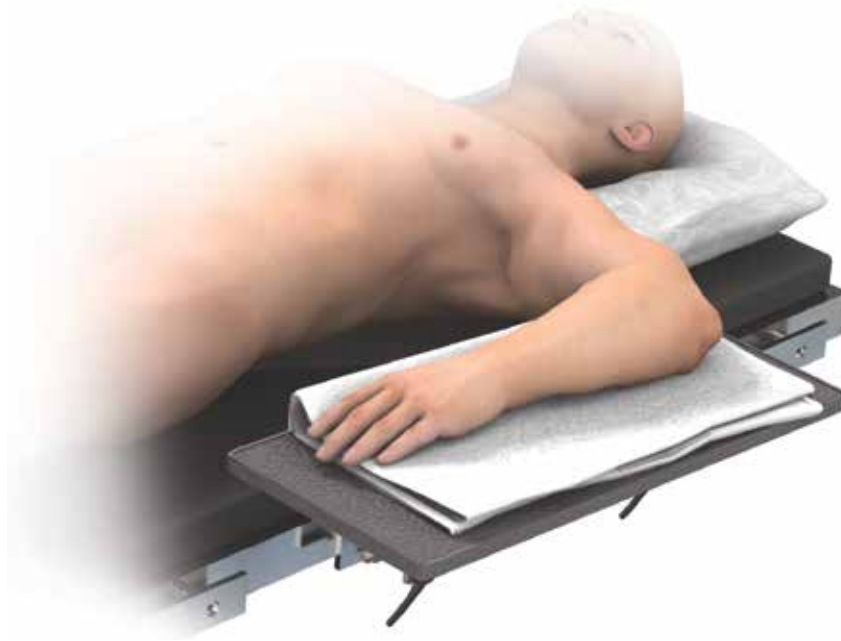

Figure 1

Introduction

For the treatment of recalcitrant lateral epicondylitis refractory to non-operative measures, multiple operative techniques have been proposed. Most procedures involve debridement of the damaged segment of the common extensor origin and some type of repair of the remaining functional tendon. The technique outlined in this guide follows the principles of the Garden Procedure first proposed by R. S. Garden in 1961 in a modified and simplified approach. Utilizing the efficiency, ease of deployment, and secure fixation of the JuggerKnot anchor allows a straightforward surgical procedure to accomplish these steps.

In patients with smaller elbows, or if the preference is to avoid complete detachment of the extensor origin, the technique by Nirschl and modified by Plancher and Bishai¹ may be substituted, which is noted on page 8.

Preoperative Preparation and Positioning

The patient is positioned supine with a “Hand Table” attachment to the operating table. A layer of bath blankets is placed beneath the elbow and forearm to position the arm parallel to the table with the elbow flexed 70 to 90 degrees (Figure 1).

A tourniquet is applied high on the operative arm. The limb is exsanguinated and the incision site injected with local anesthetic.

This material represents the surgical technique utilized by Jeffrey Nacht, M.D. Biomet does not practice medicine. The treating surgeon is responsible for determining the appropriate treatment, technique(s), and product(s) for each individual patient.

JuggerKnot Soft Anchor–1.4 mm Short

Lateral Epicondylitis Repair

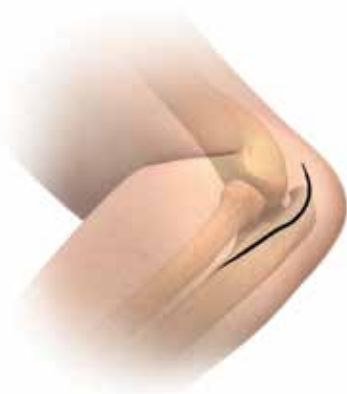

Figure 2

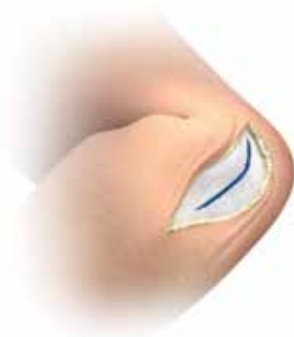

Figure 3

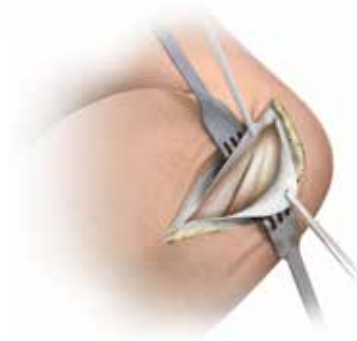

Figure 4

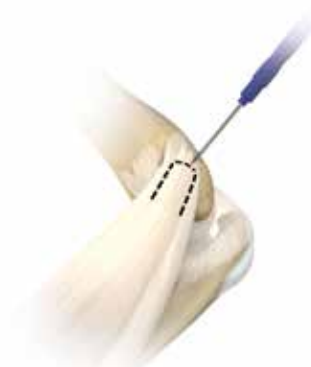


Figure 5

Incision

The incision is a 6 cm gently curving posterolateral approach beginning 2 cm proximal and 1 cm posterior to the lateral epicondylar prominence and following the skin fold distally. The incision is carried 1 cm posterior to the epicondyle and extended into the forearm for 3 cm, along the posterior edge of the radiocapitellar joint (Figure 2).

Dissection

Subcutaneous dissection is carried down to the deep antebrachial fascial layer, which is marked for later closure (Figure 3). Retracting this layer exposes the common origin of the Extensor Carpi Ulnaris, Extensor Carpi Radialis Brevis and Anconeus (Figure 4). The edge of this origin is divided and elevated with a needle tipped cautery (Figure 5).

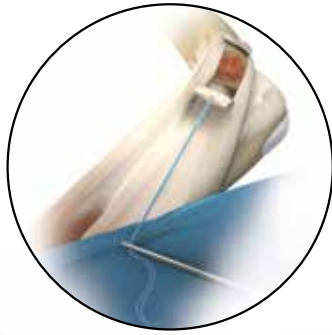


Figure 6a




Figure 8a

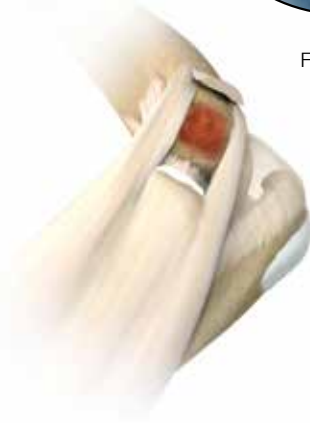

Figure 6

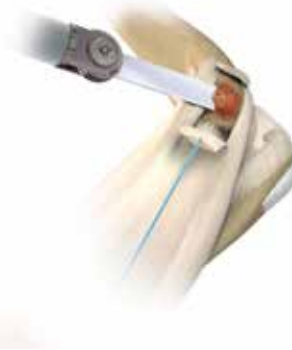

Figure 7

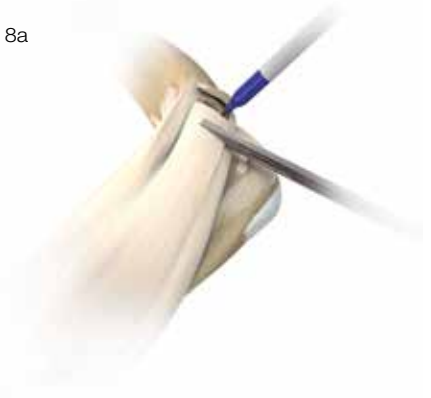

Figure 8

Dissection (cont.)

This creates a curved, tongue-shaped full thickness layer, which can be retracted distally. Dissection is carried down to the superior posterior edge of the epicondyle, which invariably uncovers a large hypertrophic spur of the lateral humeral epicondyle (Figure 6). The full thickness flap is dissected distally off the bone to the level of the joint capsule. Although the joint is not intentionally opened, sometimes the capsule of the joint will be violated. If the joint was accidentally opened or found to be opened, it will seal with a proper closure using nonabsorbable sutures.¹ A stay suture is placed in the flap and clamped distally to the drapes to prepare the epicondyle (Figure 6a).

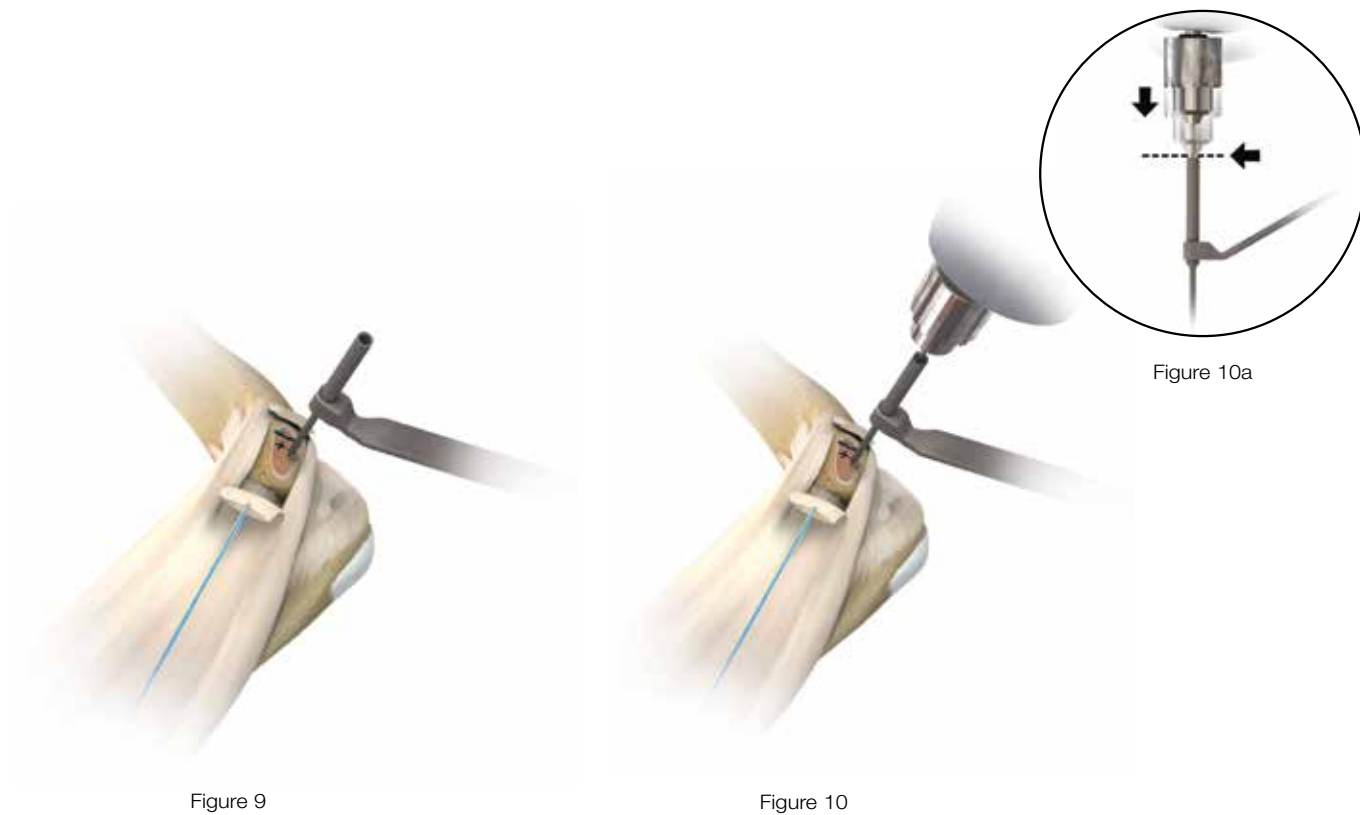
Bone Preparation

Next a small oscillating saw or rongeur is used to debride the hypertrophic bone and to create a flat surface for reattachment of the tendon (Figure 7). The deep surface of the tendon is inspected for degenerative angiofibrotic tendinosis tissue, which is dissected away to expose healthy deep tendon surface.

The tendon will be placed back on the bony surface and its planned reattachment site is marked with a marker or cautery for anchor placement (Figure 8). This avoids over-tensioning the tendon as the sutures are tied. The flap is again retracted to view the marked location for the two Juggernaut anchors that will be deployed into the epicondyle in a line perpendicular to the long axis of the tendon (Figure 8a).

JuggerKnot Soft Anchor–1.4 mm Short

Lateral Epicondylitis Repair



Placement of the JuggerKnot Guide

Place two JuggerKnot Soft Anchors-1.4mm Short. The first anchor should be placed slightly more anteriorly and the second anchor should be placed more posteriorly into the prepared bed of bone. Start by placing the JuggerKnot guide onto the bone surface (Figure 9).

Without moving the guide insert the JuggerKnot 1.4mm Short drill bit into the power drill to the proximal laser-etch line to ensure appropriate depth as the collar of the drill contacts the back of the guide. Advance the drill until contact is made with the guide (Figures 10, 10a).




Figure 11

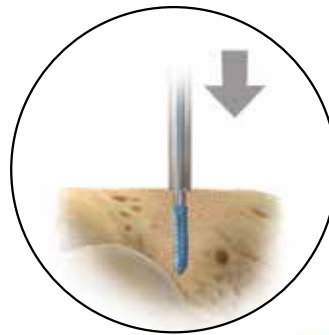


Figure 11b

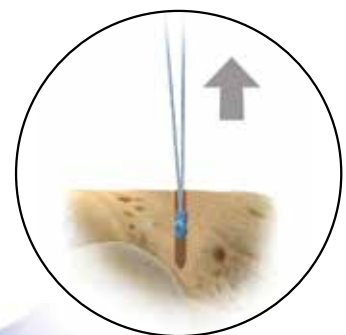


Figure 12a

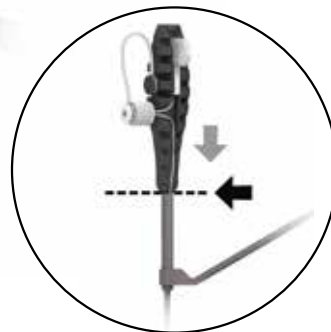


Figure 11a

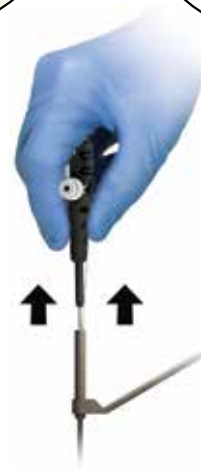

Figure 12

Insert Anchor

Remove the drill. **Caution must be taken to maintain precise guide position over the pilot hole during removal. While maintaining the guide position firmly against the bone, align the luer cap on the implant inserter handle with the slot of the guide, and insert the JuggerKnot Soft Anchor through the guide and into the pilot hole. Lightly mallet to fully seat the anchor into bone (Figures 11, 11a, 11b).**

Deploy Anchor

Once the anchor has been fully seated into the reattachment site on the surface of the epicondyle, lightly pull back on the anchor inserter handle to set the anchor (Figures 12, 12a).

JuggerKnot Soft Anchor–1.4 mm Short

Lateral Epicondylitis Repair



Figure 13

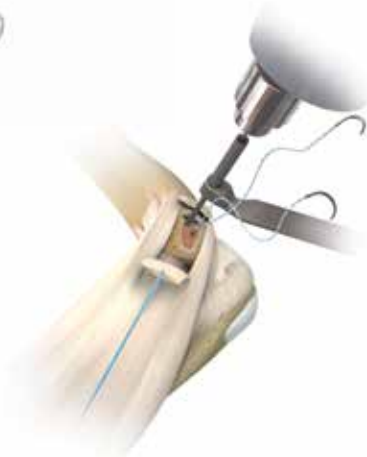


Figure 14

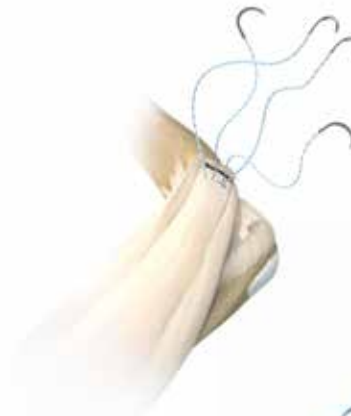

Figure 15




Figure 16

Deploy Anchor (cont.)

Release the suture from the handle by unscrewing the suture retention feature and remove the needles from the middle of the guide (Figure 13). Remove the anchor inserter and guide. Lightly pull on both sutures to set the anchor and verify the sutures slide smoothly.

Follow the same steps for the deployment of the second anchor (Figure 14).

Attachment of Tendon

Using the needles attached to the JuggerKnot Soft Anchor (2,T-5 Needles), the MaxBraid sutures are passed from the deep to the superficial surface of the tendon and tied (Figure 15). **The sutures are NOT CUT.** Next, the same sutures are passed into the proximal edge of the common extensor origin, tucking this layer over the reattached tendon edge in a “pants-over-vest” manner (Figure 16). This will cover the bone left exposed by the distally displaced tendon origin.

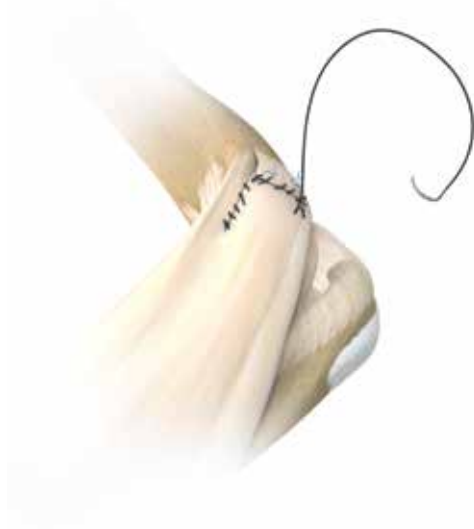

Figure 17

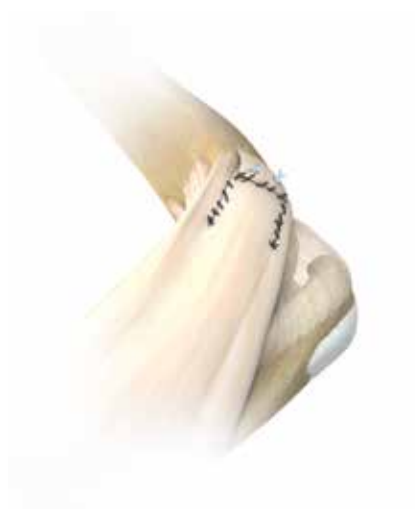

Figure 18

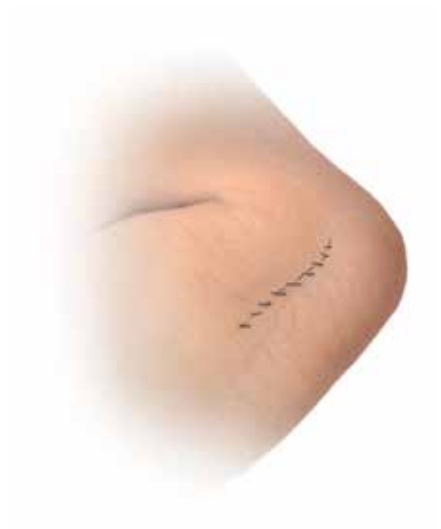

Figure 19

Attachment of Tendon (cont.)

Next, the common extensor origin repair is reinforced and completed with a running suture of 2-Vicryl or similar absorbable suture, following the curve of the detachment site. The antebrachial fascial layer is then repaired with 2-0 Vicryl (Figure 17).

Closure

The deep antebrachial fascia is repaired with 2-0 Vicryl (Figure 18). The subcutaneous and skin closure is completed using the surgeon's preferred technique (Figure 19). A light padded dressing is applied over the olecranon and lateral elbow, followed by a layer of sterile Webril. A posterior plaster splint is applied and secured with an elastic wrap. The elbow is positioned at 90 degrees of flexion in a sling.

Postoperative Care

The dressing and splint are removed at one week postoperatively. This repair is very secure and allows for early mobilization. Hand use is encouraged immediately postoperatively. After one week, a light dressing is applied and early elbow motion is encouraged. At three weeks the patient may begin physical and hand therapy to regain range of motion and dexterity. At four weeks strengthening may begin.

JuggerKnot Soft Anchor–1.4 mm Short

Lateral Epicondylitis Repair

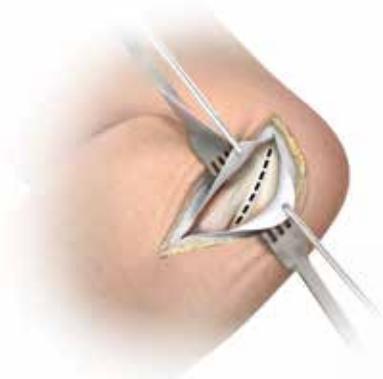

Figure 20

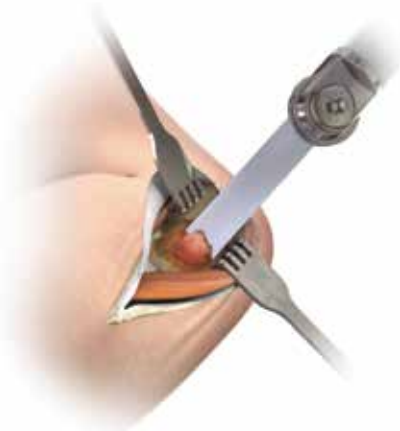

Figure 21

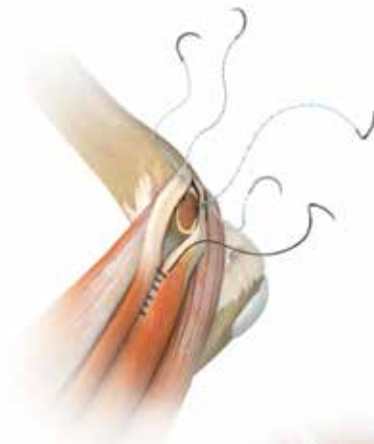

Figure 22

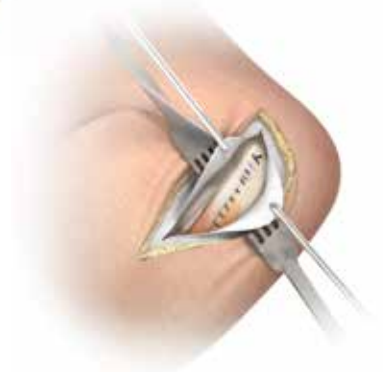


Figure 23

Alternate Technique

As noted in the introduction, in patients with smaller elbows, or if the preference is to avoid complete detachment of the extensor origin, the technique by Nirschl and modified by Plancher and Bishai¹ may be substituted. Their technique involves an identical approach down to the common extensor origin. Instead of creating a tongue-shaped flap, the origin is split longitudinally between the ECRB/ECRL and the EDC along their fibers, at its central point and retracted to expose the underlying epicondylar osteophyte (Figure 20). The epicondyle is similarly debrided to a flat surface through the interval in the tendon layer and all necrotic angiofibroblastic tissue and torn tendon fibers are excised along with any granulation tissue (Figure 21).

Next two JuggerKnot anchors are deployed into the bony surface of the epicondyle, one under each edge of the tendon (Figure 22). The sutures are passed through the two limbs of the extensor origin and left untied while the longitudinal split in the tendon is repaired with a running suture of braided polyester (non-absorbable) or Vicryl (absorbable) size 0 suture, according to the preference of the surgeon. The sutures from the anchors are then tied over the surface of the tendon (Figure 23). The closure of the antebrachial fascia and skin are carried out as noted on page 7 (Figures 18, 19).

Ordering Information

JuggerKnot Soft Anchor Short

Part Number	Size	Description
912068	1.4 mm Short	JuggerKnot Soft Anchor Short w/Needles Single Loaded
912069	1.4 mm Short	JuggerKnot Soft Anchor Short w/Needles Package of 10
912071	1.4 mm Short	JuggerKnot Soft Anchor Short Drill Bit (Disposable) Sterile
912072	1.4 mm Short	JuggerKnot Soft Anchor Short Guide (Reusable) Non-Sterile
912073	1.4 mm Short	JuggerKnot Soft Anchor Short Disposable Kit
912075	1.4 mm Short	JuggerKnot Soft Anchor Short Implant System

References

1. K Plancher, MD, MS, S Bishai, DO, MS. Open Lateral Epicondylectomy: A Simple Technique Update for the 21st Century. Techniques in Orthopaedics. 2006 21(4):276-82.

This material is intended for health care professionals and the Biomet sales force only. Distribution to any other recipient is prohibited. All content herein is protected by copyright, trademarks and other intellectual property rights owned by or licensed to Biomet Inc. or its affiliates unless otherwise indicated. This material must not be redistributed, duplicated or disclosed, in whole or in part, without the express written consent of Biomet.

Check for country product clearances and reference product specific instructions for use. For complete product information, including indications, contraindications, warnings, precautions, and potential adverse effects, see the package insert and Biomet's website.

This technique was prepared in conjunction with a licensed health care professional. Biomet does not practice medicine and does not recommend any particular orthopedic implant or surgical technique for use on a specific patient. The surgeon is responsible for determining the appropriate device(s) and technique(s) for each individual patient.

Not for distribution in France.

Vicryl is a registered trademark of Johnson & Johnson Corp.

Webril is a registered trademark of International Paper Company Corp.

Indications for use and contraindications for use for the Juggernaut Soft Anchor–1.4 mm Short are as follows:

INDICATIONS

The Juggernaut Soft Anchors are intended for soft tissue to bone fixation for the following indications:

Shoulder

Bankart lesion repair
SLAP lesion repair
Acromio-clavicular repair
Capsular shift/capsulolabral reconstruction
Deltoid repair
Rotator cuff tear repair
Biceps tenodesis

Foot and Ankle

Medial/lateral repair and reconstruction
Mid and forefoot repair
Hallux valgus reconstruction
Metatarsal ligament/tendon repair or reconstruction
Achilles tendon repair

Elbow

Ulnar Radial collateral ligament reconstruction
Lateral epicondylitis repair
Biceps tendon reattachment

Knee

Extra-capsular repair: MCL, LCL, and posterior oblique ligament
Iliotibial band tenodesis
Patellar tendon repair
VMO advancement
Joint capsule closure

Hand and Wrist

Collateral ligament repair
Scapholunate ligament reconstruction
Tendon transfers in phalanx
Volar plate reconstruction

Hip

Acetabular labral repair

CONTRAINDICATIONS

1. Infection.
2. Patient conditions including blood supply limitations and insufficient quantity or quality of bone or soft tissue.
3. Patients with mental or neurologic conditions who are unwilling or incapable of following postoperative care instructions or patients who are otherwise unwilling or incapable of doing so.
4. Foreign body sensitivity. Where material sensitivity is suspected, testing is to be completed prior to implantation of the device.

BIOMET
SPORTS MEDICINE

One Surgeon. One Patient.

©2014 Biomet Sports Medicine • Form No. BMET0263.0-GBL • REV0714



Legal Manufacturer
Biomet Sports Medicine
56 East Bell Drive
P.O. Box 587
Warsaw, Indiana 46581
USA



Authorised Representative
Biomet UK Ltd.
Waterton Industrial Estate
Bridgend, South Wales
CF31 3XA
UK

CE0086

www.biomet.com