

Anatomical Shoulder™ System

Surgical Technique



Disclaimer

This document is intended exclusively for physicians and is not intended for laypersons.

Information on the products and procedures contained in this document is of a general nature and does not represent and does not constitute medical advice or recommendations. Because this information does not purport to constitute any diagnostic or therapeutic statement with regard to any individual medical case, each patient must be examined and advised individually, and this document does not replace the need for such examination and/or advice in whole or in part.

Information contained in this document was gathered and compiled by medical experts and qualified Zimmer personnel. The information contained herein is accurate to the best knowledge of Zimmer and of those experts and personnel involved in its compilation. However, Zimmer does not assume any liability for the accuracy, completeness or quality of the information in this document, and Zimmer is not liable for any losses, tangible or intangible, that may be caused by the use of this information.

Surgical Technique Anatomical Shoulder System

Table of Contents

Preoperative Planning

Template Options	5
Preoperative planning – humerus	5
Preoperative planning – glenoid	6
Glenoid component	7

Surgical Technique

Patient Positioning and Surgical Approach	8
--	---

Humeral Head Resection

Retrotorsion (i.e. Retroversion) Adjustment	10
Implantation of the Prosthesis into the Humeral Shaft	16

Glenoid Preparation	17
----------------------------	----

Pegged Glenoid Component	18
Keeled Glenoid Component	19
Cementing	20

Postoperative Treatment	20
--------------------------------	----

Special Version for Setting Fractures	21
--	----

Revision	23
-----------------	----

Removal of Anatomical Head	23
-----------------------------------	----

Removal of Implant Stem	25
--------------------------------	----

Preparation and Description of Assembly of the Instruments

Assembly Block for Humeral Head and Stem	26
Assembly and Disassembly of Impactor	27
Charging the Impactor	27
Review of the Instrument Trays	28

Preoperative Planning

Three radiographic images of the shoulder joint are required for planning the operation:

1. Full-size anterior-posterior view with neutral rotation (0°), centered on the articular cavity
2. Axial view
3. CT scans for planning the glenoid insertion

Preoperative Planning – Humerus

After aligning the humeral stem on the anterior-posterior x-ray at 0°, place the humeral head template on the stem template and determine the size of the head of the prosthesis.

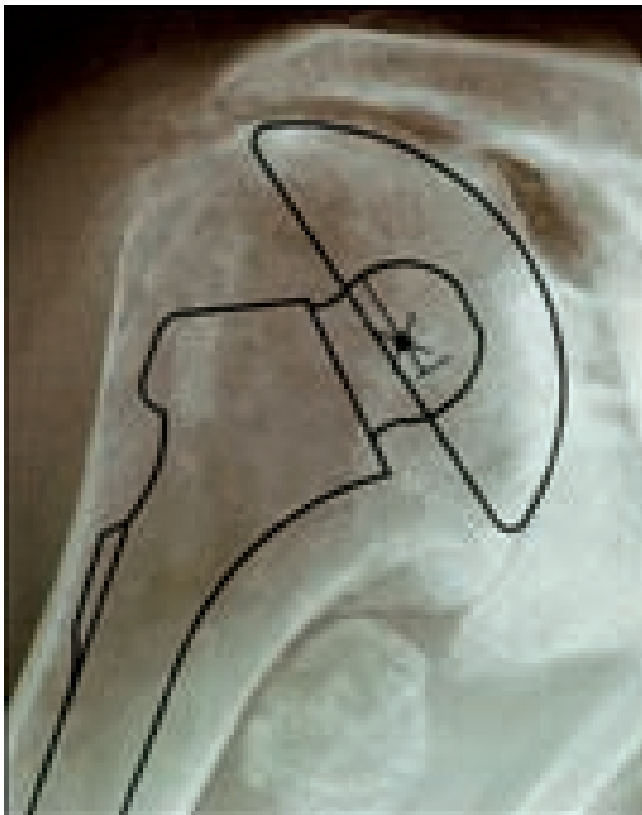If there is marked deformation of the head, planning should be based on the healthy contralateral joint.

Estimate the size of the stem of the prosthesis on the basis of the anterior-posterior and axial x-rays.

The stem should approximately fill the medullary canal, both proximally and distally. Eccentricity and retrotorsion (i.e. retroversion) are adjusted intra-operatively.

The *Anatomical Shoulder Prosthesis* allows a defined retrotorsion (i.e. retroversion) angle range between -30° and +30°. The gradual adjustment of the eccentricity of the *Anatomical Shoulder Prosthesis* which takes this into account is from 2mm (diameter 40mm) to 7mm (diameter 52mm).

For proximal fractures of the humerus, please use the *Anatomical Shoulder Fracture System*. See surgical technique Lit. No. 97-4223-003-00.



Template Options

Templates *Anatomical Shoulder System*

- *Anatomical Shoulder* Humeral Stem, Cemented/Uncemented (Press-Fit)
Lit.No. 06.01313.000
- *Anatomical Shoulder* Humeral Stem Revision, cemented
Lit.No. 06.00641.000
- *Anatomical Shoulder* Humeral Head
Lit.No. 06.00642.000

Note:

X-ray templates are magnified by 10%.

Preoperative Planning – Glenoid

Preoperative CT investigation is recommended whenever a total shoulder prosthesis is used. If there is a defect in the posterior glenoid, this must be corrected either by corrective reaming (as described below) or by bone reconstruction (using the resected head).

As illustrated below, measure the first horizontal CT section below the tip of the coracoid process and assess the glenoid version (α) (Fig. a) (any osteophytes must be identified and not taken into consideration). Determine the desired amount of correction. The typical anatomical retroversion is between 0° - 10° . In the example below, the actual retroversion $\alpha = 20^{\circ}$ is corrected by 15° (Fig. b), resulting in 5° of final retroversion (Fig. d).

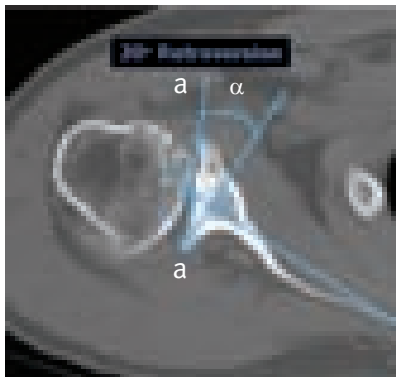


Fig. a

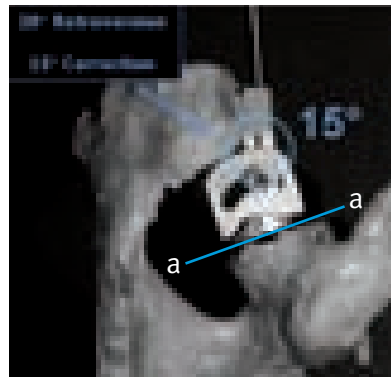


Fig. b

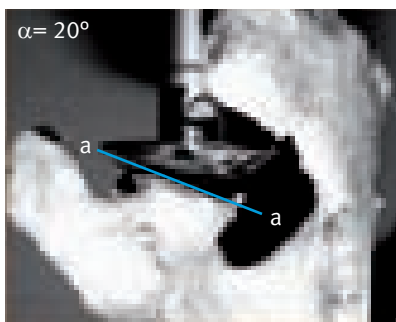


Fig. c

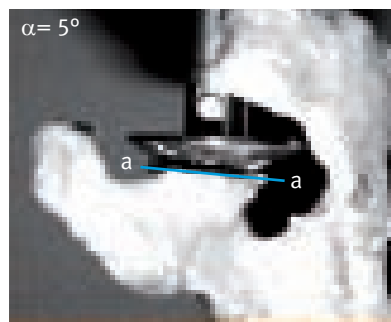


Fig. d

Enter the correction angle you have calculated on the glenoid positioning guide. Care must be taken both while drawing and during surgery, to ensure that the glenoid positioning guide lies on plane a-a (Fig. b).

Carry out cranio-caudal alignment of the Kirschner Wire under visual monitoring.

Then set this correction angle on the glenoid positioning guide, keeping in mind that one graduation mark corresponds to 5° (see page 17).

Optional

If the need of an exact inferior/superior (α_1, β_1) and/or retroversion correction (α_2, β_2) is identified during preoperative planning with CT scans, the optional 3D Guiding Instrument (with 5° increment laser marks) can be used (Fig. e).

A preoperative CT scan is recommended for the purpose of determining the possible need for realignment of the articulating surface. The target value is a typical anatomical retroversion between 0° and 10° (retro) (Fig. d).

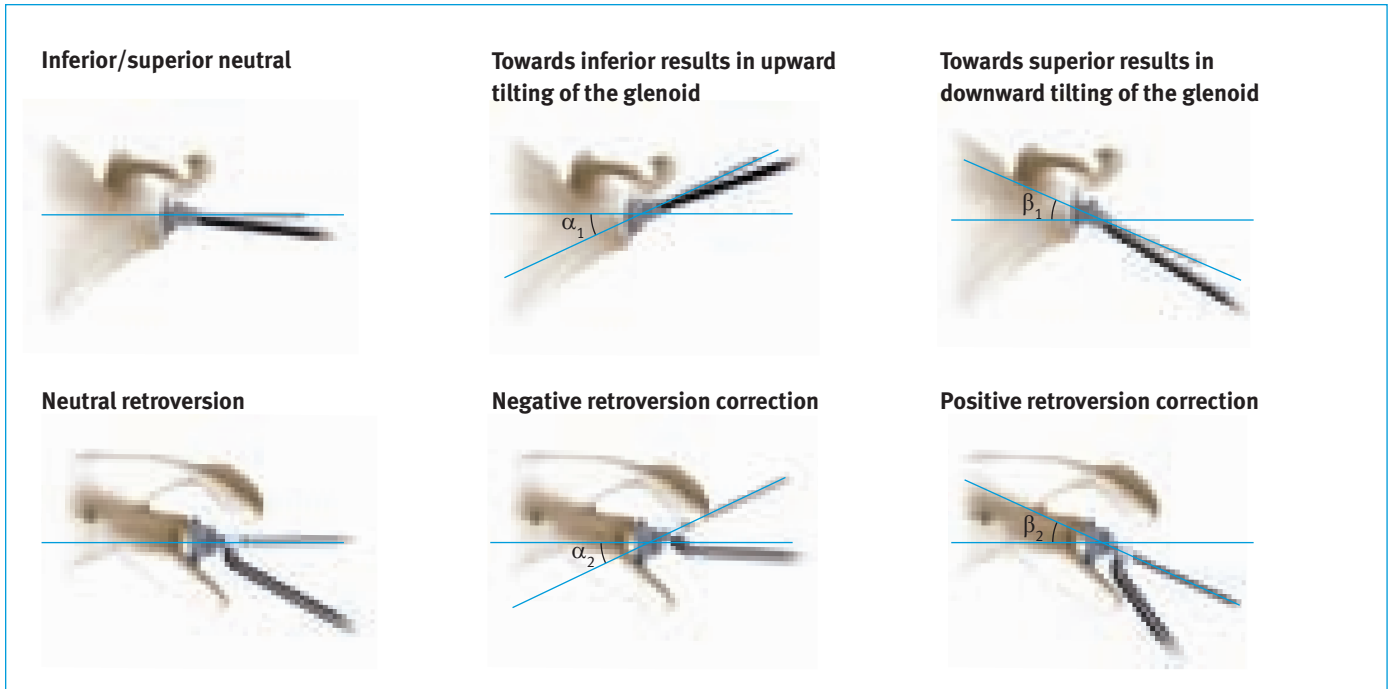






Fig. e


The Glenoid Component

The mismatch of the radii of the glenoid and of the humeral components allows a slight rolling and sliding movement of the head to absorb shear loads.

The glenoid surface can be reamed with the available reamers to achieve congruence between the anatomical glenoid and the rear surface of the glenoid component, thereby minimizing the rocking-horse effect, so that a low glenoid loosening rate can be expected.

The convex design preserves more bone, reduces lumped and shear loads and responds better to eccentric loads than a design with a flat posterior surface.

Humeral head- 	glenoid "mismatch" in mm		
	 S	 M	 L
Ø 40	6.5	8	10
42	6	7.5	9.5
44	5	6.5	8.5
46	3.5	5	7
48	2.5	4	6
50	2	3.5	5.5
52	1	2.5	4.5

 preferred combination

Surgical Technique

Patient Positioning and Surgical Approach

The patient should be placed in a beach chair position on the edge of the operating table (Fig. 1). The arm must be freely movable, and it must be able to extend fully. An armrest is optional.



Fig. 1

Make a skin incision in a straight line starting from the lateral edge of the coracoid as far as the insertion of the deltoid muscle. Seek out the cephalic vein between the deltoid muscle and



Fig. 2

the pectoralis major muscle. Make the approach medial to the vein (Fig. 2).

After exposing the subacromial space, retract the deltoid muscle with a deltoid retractor.

Retract the common tendon of the short biceps and the coracobrachialis muscles with a Langenbeck retractor (Fig. 3).



Fig. 3

Rotate the arm outwards as far as possible and bring the subscapularis muscle into the field of vision (Fig. 4).

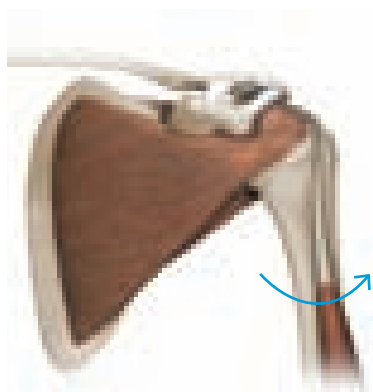


Fig. 4

Make a vertical incision 1cm lateral to the muscle tendon junction of the subscapularis, so that approximately 1cm of tendon remains attached to the muscle. Alternatively, it is possible to detach the tendon of the subscapularis muscle either subperiostally or with an osteotome from the lesser tuberosity, securing it back into place transosseously after the operation (see also page 9, Figure 6).


Mobilize the subscapularis muscle by means of a capsulotomy and looping 4 to 5 strong non-absorbable sutures around it (Fig. 5). An incision into the coracoacromial ligament should be made only in exceptional cases.



Fig. 5

Adduct the arm and put the humerus retractor (ring retractor) into place, so that the glenoid can be exposed. Pulling on the subscapularis muscle, to expose and protect the axillary nerve with the arm both adducted and flexed.

If there is pronounced internal rotation contracture, it may be necessary to undertake partial release of the subscapularis muscle from the fossa (Fig. 6).



After exposing the axillary nerve, remove the ring retractor and dislocate the humerus by rotating it externally. The proximal end of the humerus is now free. Keep the arm adducted, rotated externally, and extended. Place a blunt Hohmann retractor on the calcar and carefully remove all the osteophytes from the anatomical neck using a rongeur. Expose the attachment of the cartilage to the humeral head by inserting an 8mm hook behind the biceps tendon (Fig. 7).



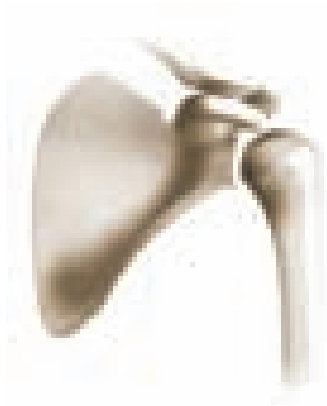
Humeral Head Resection

The humeral head should be resected exactly at the level of the anatomical neck.

In the superior and anterior superior aspects, the anatomical neck corresponds to the insertions of the tendons of the cuff (supraspinatus and uppermost section of the subscapularis). In the inferior aspect, there is a smooth transition between the cartilage of the head and the cortical bone of the humerus.

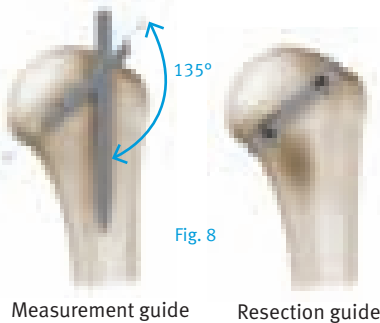
In the posterior aspect, in the region of the infraspinatus and teres minor, is the sulcus, which is a groove of 6 to 8mm in length, without cartilage or attached tendons.

The resection must start exactly on the cartilage. Do not resect the cartilage-free area.



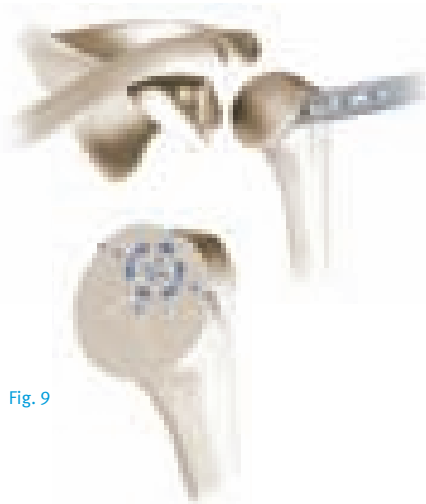The humeral head is now resected exactly at the height of the anatomical neck with the aid of an oscillating saw – i.e. in the cartilage-covered section of the head.

The resection is in the caudal direction. Measurement and/or resection guides can be used for orientation or assistance (Fig. 8). In this case the inclination is 135 degrees.



Retrotorsion (i.e. Retroversion) Adjustment

The *Anatomical Shoulder Heads* allow a retrotorsion angle between -30° and $+30^\circ$.



After the osteotomy of the humeral head, the point of insertion of the reamer can be marked with a 3mm awl under the highest point of the resection, directly medial to the bicipital tendon (Fig. 9).

For this purpose, the arm is externally rotated and extended, and the elbow is rested on the body.

If a Glenoid is Used

The plane of the humeral resection can be protected with a disk-shaped protector (Fig. 10). Disks of three different diameters (40, 44 and 48) are available. The pins on the lower side of the disks are inserted at the level of the incision (glenoid preparation and implantation; see page 17).



Fig. 10

After the point of insertion has been determined, the medullary cavity is opened, starting with a size 7 reamer (Fig. 11).

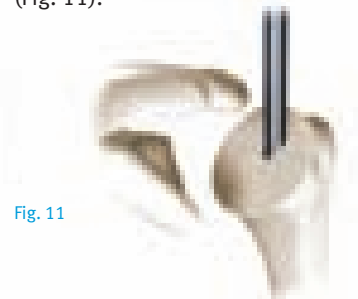

Fig. 11

The medullary cavity is gradually widened, using reamers of increasing sizes as required – sizes 9, 10.5, 12 and 14.

Note

The depth of penetration is defined by the uppermost tooth. Care should be taken to ensure that the uppermost tooth of the reamers is fully inserted into the medullary cavity. If a revision stem is used, the reamer should be inserted all the way down to the black etch line.

After opening the medullary canal, the proximal section of the humerus is prepared with the aid of modular rasps, starting with rasp size 7 (Fig. 12).



Fig. 12

The fin is directed towards a point approximately 9mm behind the sulcus. The proximal section of the humerus is then prepared stepwise with rasps of size 9, 10.5, 12 and 14, up to the size of the previously used reamer (Fig. 13).

Note

The cemented stem is available in sizes 7, 9, 12 and 14. The uncemented (press-fit) stem is available in sizes 7, 9, 10.5, 12 and 14.




Fig. 13




Fig. 14

Retroversion Adjustment Technique

Insert the Alignment Rod into the appropriate retroversion hole on the Rasp Handle. Use the right or left hole for the corresponding shoulder side and the preferred hole for orientation to the forearm or to the condyles (Fig. 14)

Continue rasping with the elbow bent at 90° parallel to the axis of the epicondyle of the distal humerus. This sets the retroversion at 18°.




Fig. 15

Optional

Optional

In order to perform a superior-lateral approach, the Straight Rasp Handle can be used (Fig. 15).

Care should be taken to ensure that the rasps are fully inserted into the humerus, i.e. until the movable cross-pin is visible on top and contacts both anterior and posterior metaphyseal surfaces (Fig. 16).

Note

If full insertion of the rasp to this extent is not successful, the uncemented (press-fit) stem of this size may not be used.




Fig. 16

The Rasp Handle is now removed and the modular rasp left in the humerus. The rasp is now seated 5mm below the resection line (Fig. 17).




Fig. 17

The rasped lateral fin is now visible posterior to the bicipital tendon.

Cement mantle:

The average thickness of the cement mantle is 1mm.

Press-fit:

The average press-fit is 0.55mm. The distal fins generate the major part of the press-fit.

Optional

Additional fixation of the modular rasp in the humerus can be performed by inserting a Rasp Fixation Screw into the modular rasp (Fig. 18) (this is recommended for poor bone quality). This ensures that the rasp will not subside when the humeral head is impacted onto it.

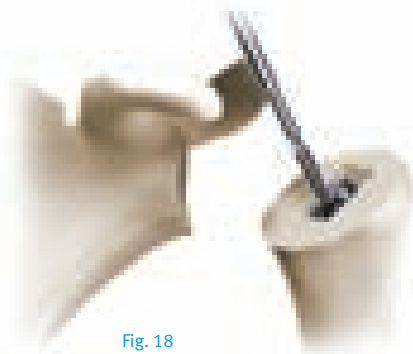

Fig. 18

The preparation of the humeral canal is now complete.

The size of the head of the prosthesis to be used is determined by means of a comparison with the resected humeral head and, in particular, with the resection area of the humerus. If osteophytes are present, they must be removed before this comparison. The diameter is the most important criterion for head size (Fig. 19).




Fig. 19

The diameter is fixed as the first parameter.




Fig. 20

The head height must also be selected for diameters of 48, 50, 52mm (Fig. 20).

The selected humeral head trial prosthesis is inserted onto the trial Ball-Taper (Fig. 21).



Fig. 21

All Grub Screws must be loosely tightened in place outside the internal ball of the head (Fig. 21a).

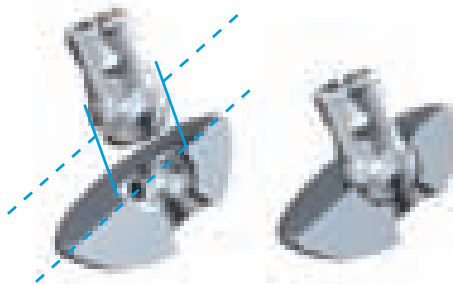


Fig. 21a

The loosely connected humeral trial prosthesis is placed on the modular rasp in the humerus, so that the underside of the head is resting on the humerus (Fig. 22).



Fig. 22

The Trial Head is turned with the aid of a 2.5mm Hex Screwdriver, until it covers the area of the humeral resection incision, resulting in an exact anatomical restoration of the resected head (Fig. 23, 24).

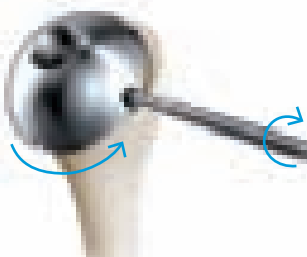


Fig. 23

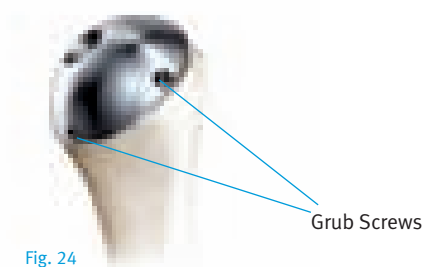


Fig. 24

Use the Grub Screws to keep the Trial Head in proper position. Tighten two screws that face you first; then remove the Head and tighten the remaining three screws. Place the Trial Head and Ball-Taper back on the rasp to begin trial reduction.

The offset laser marking of the humeral head trial prosthesis is transferred to the humerus by an incision and the humeral trial prosthesis is then removed from the humerus.

The definitive prosthesis stem (of the size determined by the last used modular rasp), the Ball-Taper component, the Expansion Cone and the Set Screw are unpacked.



cemented

uncemented

Ball-Taper component

Expansion Cone Set Screw

The Expansion Cone is then placed into the Ball-Taper component (Fig. 25).




Fig. 25

The Expansion Cone is carefully fixed into the Ball-Taper component using the Insertion Rod, without causing any premature spreading of the Ball-Taper component (Fig. 26).




Fig. 26

The definitive prosthetic head is now unpacked. The size of the head has been defined by the previously used Trial Head.

The head is now inserted into the Ball-Taper component as shown (Fig. 27).



Fig. 27

The implant is now loosely assembled, and the Expansion Cone is located inside the Ball-Taper component (Fig. 28).



Fig. 28

The Ball-Taper should be able to move freely in the head (Fig. 28a).

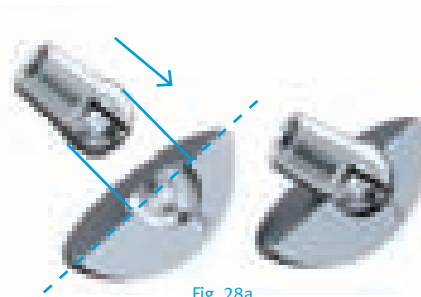


Fig. 28a

The assembled head is now fitted onto the oval internal profile of the modular rasp (Fig. 29).



Fig. 29

The head is adjusted so that it covers the resection plane of the humerus.

The gap between the under side of the head and the resection plane is required before fixation. When the head is set parallel with the incision on the humerus and the head covers the resection plane in inclination, retroversion and offset, prefix the head to the Ball-Taper component using three consecutive defined impulses from the Impactor (Fig. 30).

For instructions on charging the impactor, see page 27.




Fig. 30

Note

Care should be taken to ensure that the Impactor is pressed centrally onto the ball area of the head and up to the maximum compression of the spring before the three defined pulses are triggered.

These pulses propel the Expansion Cone inside the Ball-Taper component towards the ball. The Expansion Cone is spread and the head is prefixed on the Ball-Taper component (Fig. 31).

The prefixed head component is now removed from the modular rasp. The inclination, retroversion and offset have now all been prefixed.

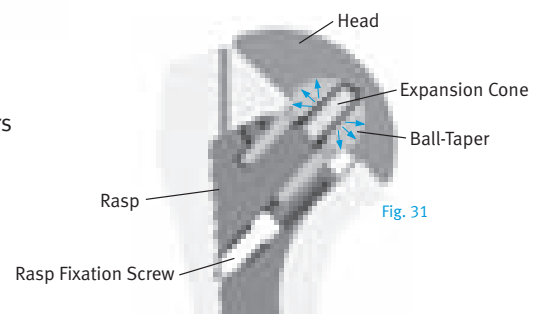


Fig. 31

Modular rasp serving as trial stem for the prosthesis

The Set Screw is unpacked and inserted from the lower side of the head into the Ball-Taper component using the 4.5mm Nut. The Set Screw is then screwed loosely into the Ball-Taper component until it sticks (Fig. 32).




Fig. 32

The head implant is then inserted into the assembled mounting block and lightly fixed with the Threaded Rod (Fig. 33).

Care should be taken to not overtighten the head/block to reduce the chance of head/Ball-Taper movement.




Fig. 33

Note

For instructions on how to assemble the Assembly Block for the Humeral Head refer to page 26.

Connect the Torque Wrench to the 4.5mm Nut.

The Set Screw is then fastened with the Torque Wrench, using the 4.5mm Nut, until it is tight (Fig. 34).

The head prosthesis has now been permanently fixed (Fig. 35) and can be carefully removed from the assembly block.

The stem prosthesis is now placed into the stem holder (Fig. 36).

Note

Before the prosthesis head can be placed on the prosthesis shaft, the cones must be carefully cleaned of blood and possible other residues.




Fig. 34

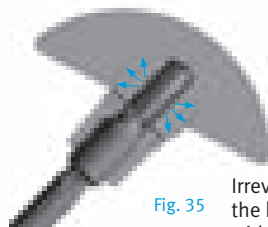


Fig. 35

Irreversible fixation of the head component with the Ball-Taper component



Fig. 36

The offset incision on the humerus is now examined to see whether this is medial or lateral and anterior or posterior on the humerus. The head prosthesis is now placed on the stem prosthesis, after appropriate rotation (Fig. 36).

The prosthesis head is now finally impacted onto the prosthesis stem with the aid of the Impactor (Fig. 37).

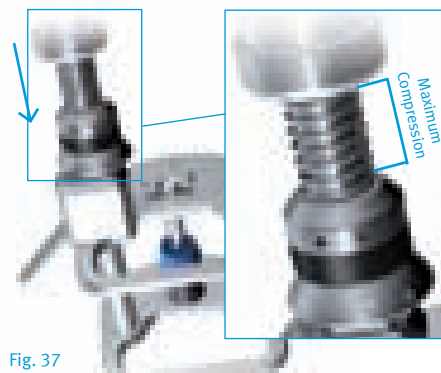


Fig. 37

Note

Care should be taken to ensure that the Impactor is centrally located on the ball surface before the defined pulse is triggered (Fig. 37).

The humeral implant has now been prepared specifically for this patient (Fig 38).

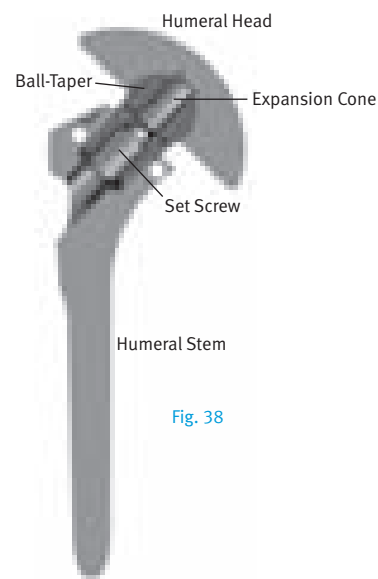


Fig. 38

Cross-section of implanted prosthesis

The modular rasp can now be removed from the humerus (Fig. 39). If the Rasp Screw has been used it must be removed first. The Rasp Handle cannot be mounted without removing this screw.




Fig. 39

If the Rasp Handle can not be attached, the modular rasp can also be removed from the humerus by means of the Rasp Extraction Instrument (Fig. 40).

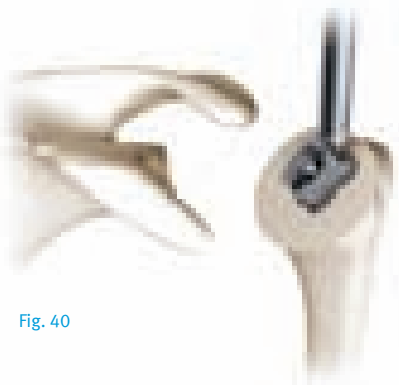


Fig. 40

Implantation of the Prosthesis into the Humeral Shaft

With the cemented prosthesis, a cement restrictor can be inserted into the humerus, followed by the cement, in a relatively fluid consistency.

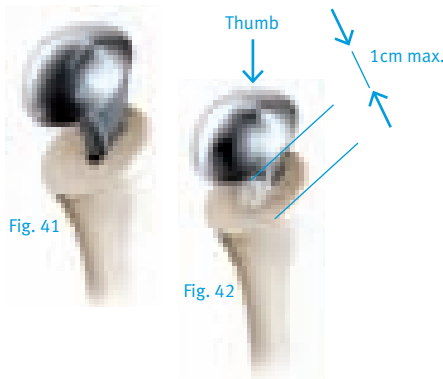


Fig. 41

Fig. 42

The implant is now inserted into the humerus (Fig. 41) by applying controlled force with the thumb on the head.

Note

If it is not possible to seat the implant with the thumb until you reach a maximum of 1cm distance (Fig. 42) between the proximal humerus resection line and the bottom of the humeral head, extract the implant and re-ream with the last rasp size used.

The lateral stem fin is used as orientation.

The implant is brought into the final position with careful blows on the Humeral Stem Impactor. This is done until the lower side of the Humeral Head is resting on the humerus (Fig. 43, 44). If the cemented prosthesis is being used, excess cement is then carefully removed).

Cement mantle:

The average thickness of the cement mantle is 1mm.

Press-fit:

The average press-fit is 0.55mm. The distal fins generate the major part of the press-fit.

The end of the subscapularis is repaired using heavy, non-absorbable sutures either end to end or with transosseous sutures. The repair is started with a suture which adapts the lateral most aspect of the rotator interval.



Fig. 43

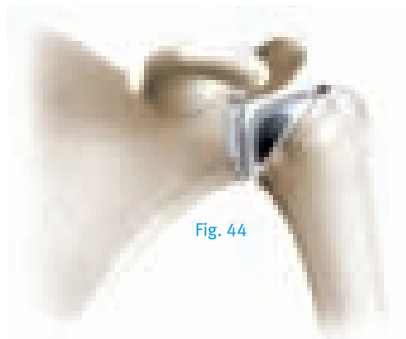


Fig. 44

Glenoid preparation and implantation see page 17.



Fig. 45

Stitch the subscapularis and the supraspinatus tendons to each other with absorbable thread (Fig. 45).

At this point, also reconstruct the rotator cuff if required.

Glenoid Preparation

After removal of all the glenoid osteophytes (Fig. 46), a ring retractor is inserted and the proximal humerus levered out posteriorly. The inferior capsule must be incised carefully preserving the axillary nerve. Attention should be paid that the axillary nerve is protected. The caudal capsule is incised and the glenoid exposed.




Fig. 46

Set the correction of version determined from the preoperative CT scan on the Positioning Guide (see page 6). Identify the optimal position for the Guide Pin and introduce the Guiding Pin/Kirschner Wire.




Fig. 47

Introduce the Guiding Pin/Kirschner Wire into the Positioning Guide.

The laser marking on the 3mm Kirschner Wire (a) must disappear slightly into the eyelet of the Positioning Guide (Fig. 47).

After this, remove the Positioning Guide over the 3mm Kirschner Wire.

The 3mm Kirschner Wire is now perpendicular to the required alignment of the articulating surface, which was determined preoperatively (see page 6).

The Reamer (Fig. 47a) and then the Cannulated Handle are mounted on the Kirschner Wire. For sclerotic glenoids the separate reamer (Fig. 47b) may be used to start the reaming process.



Fig. 47a
Oval
reamer



Fig. 47b
Sclerotic
reamer

If it is not possible to insert the Kirschner Wire, drill a hole in the center of the glenoid with the Glenoid Drill and then ream the glenoid using the Non-Cannulated Handle with the center locator (Fig. 48).

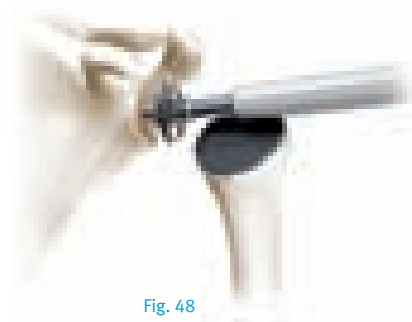


Fig. 48

Now ream the glenoid on the basis of the reamer size and ream in the new alignment of the articulating surface (Fig. 48).

The size of the last used reamer corresponds to the size of the glenoid implant.

If selection of the prosthetic components is difficult, it is generally preferable to err towards smaller heads and towards larger glenoids.

Note

All sizes of glenoids can be combined with all sizes of humeral heads (see “The Glenoid Component” page 7).

Optional

If the need of an exact inferior/superior and/or retroversion correction is identified during preoperative planning with CT scans, the optional 3D Guiding Instrument (with 5° increment laser marks) can be used.

Continue with the Pegged Glenoid preparation on page 18 or with the Keeled Glenoid preparation on page 19.

Pegged Glenoid Component

Now guide the Glenoid Drill Guide (left and right version) with the central hole along the 3mm Kirschner Wire and place it on the surface of the glenoid.

The Glenoid Drill Guide can be secured in place by means of a Cannulated Centering Peg (Fig. 49).

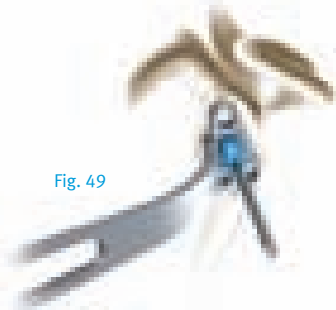


Fig. 49

The superior hole, with a diameter of 6.2mm, is now bored with the Glenoid Drill.

The Drill can be used with either the Flexible or the Rigid Shaft. These shafts have an A.O. coupling but can also be used with a chuck.

Care should be taken to ensure that drilling is continued as far as possible with the Glenoid Drill Guide (Fig. 50).

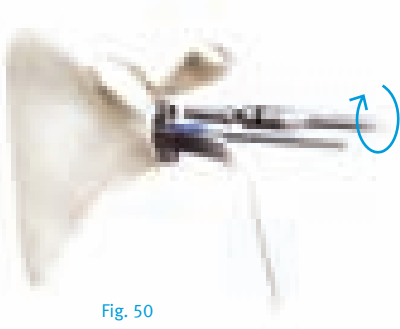


Fig. 50

The superior drilled hole is then fixed with a Centering Peg and one of the two inferior holes is drilled. The second hole is then fixed with a Centering Peg while the second inferior hole is drilled (Fig. 51).




Fig. 51

The third bored hole is now fixed with a Centering Peg and the 3mm Kirschner Wire and the middle Centering Peg are removed (Fig. 52).

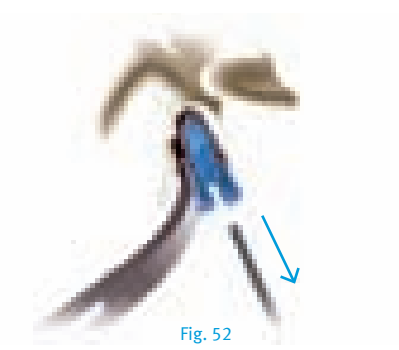


Fig. 52

Now drill the central hole (Fig. 53).




Fig. 53

Engage all the holes with the Countersink in order to enable seating of the glenoid component (Fig. 54). The Countersink can be used with either the Flexible or the Rigid Shaft.

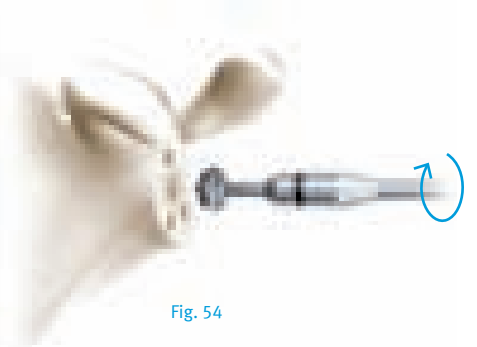


Fig. 54

Now insert the Glenoid Trial prosthesis into the prepared glenoid, using the Holding Forceps (Fig. 55).



Fig. 55

Keeled Glenoid Component

Now guide the Glenoid Drill Guide with the central hole along the 3mm Kirschner Wire and place it on the surface of the glenoid.

The Glenoid Drill Guide can be secured in place by means of a Cannulated Centering Peg.

Note

The Glenoid Drill Guide is available in two sizes: Small/Medium for the Keeled Glenoid sizes Small and Medium, and size Large for the Keeled Glenoid size Large. Both sizes are available in a left and right version.

The superior hole is drilled then fixed with a Centering Peg and the inferior hole is drilled (Fig. 56). The second hole is then also fixed with a Centering Peg. The 3mm Kirschner Wire and the Centering Peg are removed.

Now drill the central hole approximately 5mm into the glenoid. Remove the two pegs afterwards. Now drill the central hole until you have reached the Glenoid Drill Guide stop.




Fig. 56

To help ensure optimal preparation of the bone to the keel glenoid, as a final step the bone is processed into a keel with a Rasp (Fig. 57). This step gives optimal concentration of the bone.




Fig. 57

If Drill Guide of sizes Small or Medium were used, use Rasp size Small and Medium. The rasp of size Large is used, if the size Large drill guide was used.

The Glenoid Trial prosthesis is inserted into the prepared glenoid using the Holding Forceps (Fig. 58).



Fig. 58

Cementing

The Glenoid Trial prosthesis is used to test whether the seating is stable (Fig. 59).



Fig. 59

The glenoid surface and the anchoring holes are now carefully cleaned and dried. The anchoring holes are filled with bone cement, and the cement is pressed into the anchoring holes with a clean compress or using the instruments shown in Fig. 60 and 61. The Pegged Cement Impactor can be used for all three sizes Small, Medium and Large (Fig. 60).

The Keeled Cement Impactor consists of a handle and two pressurization adapters in size Small/Medium and Large (Fig. 61).

The anchoring holes are then filled where necessary, and cement is applied to the glenoid surface and the back side of the implant.



Fig. 60



Fig. 61

The implant is then cemented into place using the Glenoid Impactor (Fig. 62).

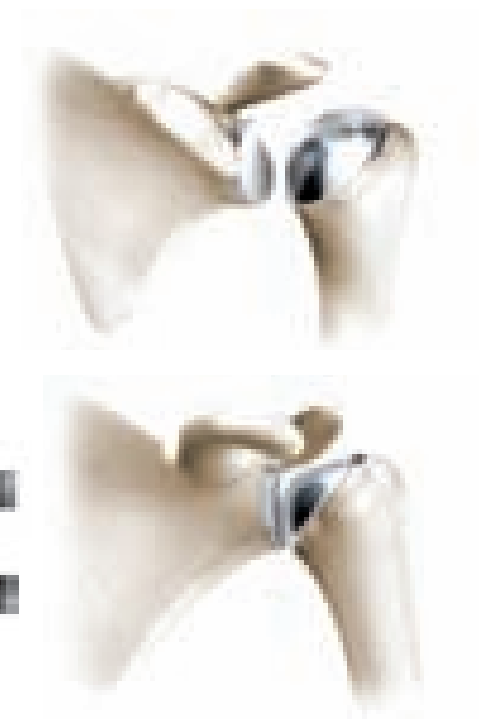


Fig. 62

Note

Do not use the Impactor on the implant while the cement is hardening.

The excess cement is immediately and carefully removed with a knife blade.



Postoperative Treatment

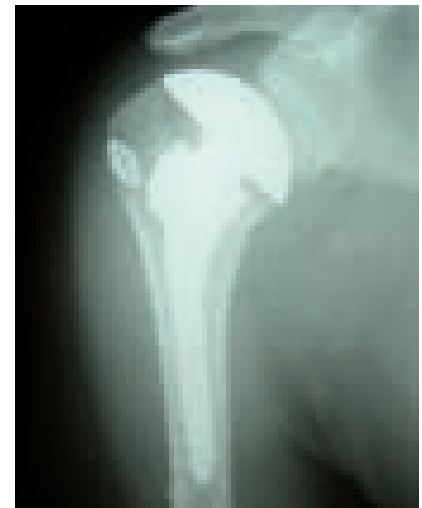It is the responsibility of the doctor to decide which postoperative treatment is appropriate depending on each patient's health condition.

The following outlines recommendations which are generally made by doctors.

On the day of the operation, pendulum exercises are generally started with passive flexing exercises, best performed using a cord passed over a roller.

From the first day after the operation, the patient takes the arm out of the immobilizing dressing several times a day to stretch his elbow.

Depending on the intraoperative findings, active exercises can be started from the third week. If the rotator cuff was sutured or reconstructed, an abduction splint may be necessary for 4 to 6 weeks.



Special Version for Setting Fractures

Note:

For proximal Humerus Fractures, please use the *Anatomical Shoulder Fracture System*.

Additionally, you can also treat a proximal humerus fracture situation with the *Anatomical Shoulder Standard System*.

Following fractures of the proximal humerus, the humerus prosthesis is set at an average retrotorsion of 18° and a mean inclination (cervicodiaphyseal angle) of 130° . Fixation of the head of the prosthesis in this position is achieved by means of the Fracture Cone with a pin that is anchored in the drilled hole provided for this purpose.

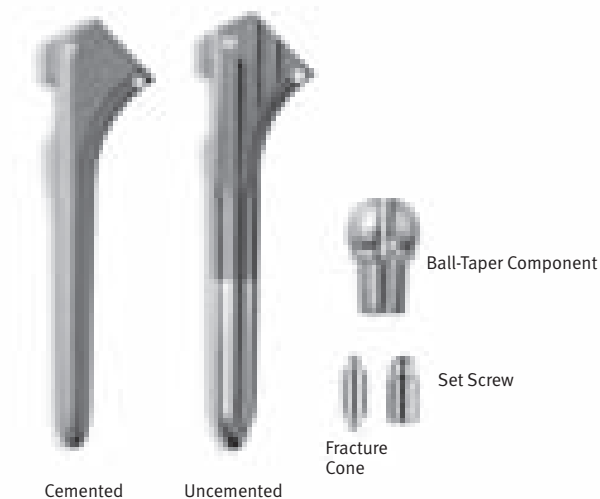
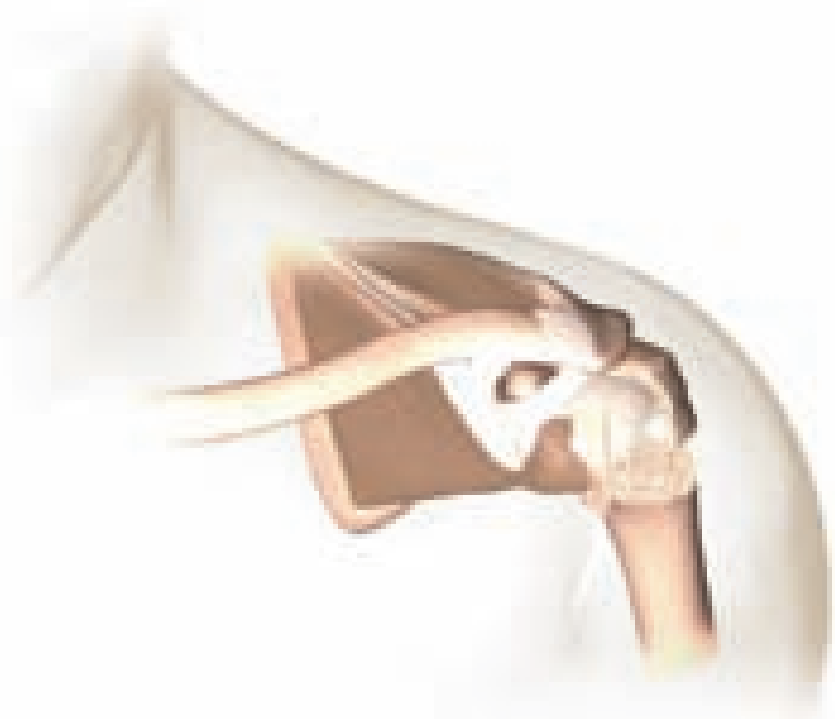Carry out preoperative planning according to the instructions provided on page 5, on the contralateral side.

Carry out the rasping and implant the humerus prosthesis with the elbow bent at an angle of 90° parallel to the axis of the epicondyle of the distal humerus. This automatically gives rise to an inclination of 130° and a retrotorsion of 18° .

After this, the tuberosities are fixed using strong thread passed through the hole in the proximal stem and the medial hole.

Unpack the permanent stem of the prosthesis and head (the size of the stem and that of the head were defined earlier on the basis respectively of the trial stem of the prosthesis and trial head used previously).

Then unpack the Ball-Taper component, the Fracture Cone and the Set Screw.



Cemented

Uncemented

Ball-Taper Component

Set Screw

Fracture Cone

Now introduce the Cone Holder for fractures into the assembly block.

A Left and a Right Cone Holder are available.



Now fit the head onto the Ball-Taper component as illustrated.



Introduce the Fracture Cone with its anchoring peg into the Ball-Taper component from the underside of the head, and secure it in place gently, using the Set Screw and 4.5mm Nut in such a way that no expansion will take place yet.




Introduce the head implant into the mounted assembly block in the Cone Holder.

After this, turn the prosthesis until the mark on the Cone Holder coincides with the one on the head, before fixing the head of the prosthesis in the assembly block with the Threaded Rod.



Before fixing the head on the Ball-Taper component, it is necessary to make sure that the laser marking on the head coincides with the one on the Cone Holder and that the head of the prosthesis is positioned perfectly on the Cone Holder.

Once this has been done, tighten the Set Screw using the 4.5mm nut with the Torque Wrench.



The head of the prosthesis is now irreversibly in place and can be removed from the assembly block, proceeding with care.

A mean inclination of 130° , an average retrotorsion of 18° and the appropriate offset have now been successfully transferred to the head implant.

The head prosthesis is now placed on the stem prosthesis, after appropriate rotation. The prosthesis head is impacted onto the prosthesis stem with the aid of the Impactor. It can now be implanted.



It must be stated that the prosthetic shaft must now be introduced exactly in neutral rotation that is in 0 degrees of version because the average version is given by the tilt of the head on the shaft.



Revision

Removal of the Anatomical Head

After exposing the axillary nerve, remove the ring retractor and sublux the humerus by externally rotating it. The proximal end of the humerus is now free. Keep the arm adducted, rotated outwards and extended. Place a blunt Hohmann retractor on the calcar and carefully remove all the osteophytes from the anatomical neck using a rongeur. Now expose the attachment of the cartilage to the humeral head by inserting an 8mm hook behind the biceps tendon.

With a cemented humeral stem the humeral head is removed of cement with a Lexer Chisel so that the extraction instrument can be applied.

The Humeral Head Extractor is now applied to the humeral head and fixed with a two-edged screw (Fig. 63). With the aid of the Extractor instrument and the Slide Hammer Weight, the humeral head is separated from the humeral stem parallel to the lower side of the humeral head (Fig. 63).

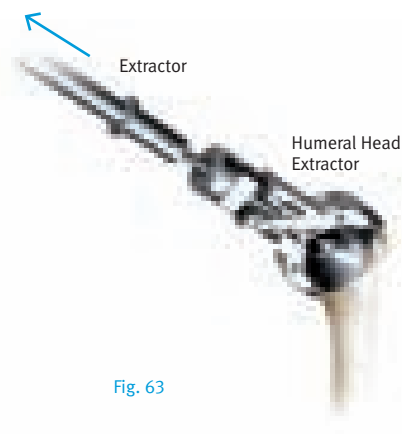


Fig. 63

To remove the cement from the thread if the humeral stem is cemented, a Drill Guide is first inserted into the oval cone of the humeral stem and then used to guide the Drill (Fig. 64).

Note:

Care should be taken to ensure that drilling is continued as far as possible.

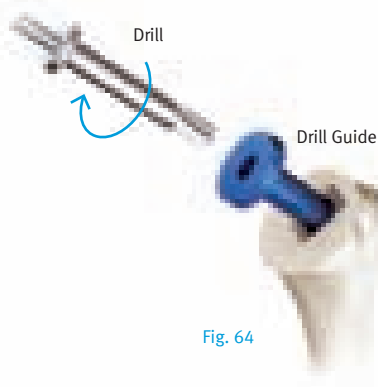


Fig. 64

Any remaining cement is now removed from the thread in the stem with the Thread Cutting Head (Fig. 65).



Fig. 65

Note:

Instruments are from Revision Tray.

The X-pin is now screwed into the humeral stem using the 2.5mm Hex Screwdriver (Fig. 66). The X-pin guides the reamer and is essential for directing and fixing the new head.

Note:

Care should be taken to ensure that the X-pin is fully screwed in and that the oval internal cone is not damaged when this happens.




Fig. 66

To remove the cement above the oval cone, use the RH Reamer (Fig. 67). Reaming is performed using the Cannulated Handle from the glenoid tray.

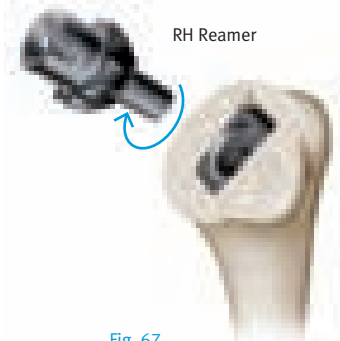


Fig. 67

The resection plane is recreated using the oscillating saw.

If implanting a glenoid, the plane of the humeral osteotomy is then protected with the humeral head protector (see page 10, Fig. 10).

Glenoid preparation and implantation can start – see page 17 of this surgical technique.

After completing treatment of the glenoid, examine the removed humeral head with the Ball-Taper fixed to it for damage.

It is the responsibility of the surgeon to establish without doubt whether the removed humeral head is still in perfect condition with the Ball-Taper fixed in place. If this is the case, the surgeon may place the same humeral head back on the humeral stem in the same position as before, positioning the oval cone with the required orientation.

The cone plug connection between humeral head and humeral stem must be clean and dry when they are impacted together.

If the removed humeral head is not in perfect condition with the Ball-Taper fixed in place, a new humeral head with a new Ball-Taper must be prepared and then inserted.

In order to trial the humeral head, the X-pin, Expansion Cone, Ball-Taper, and Trial Humeral Heads with Grub Screws will be needed (Fig.67a). Using the 2.5mm Hex Screwdriver, fully screw the X-pin into the humeral stem.




Fig. 67a

The Expansion Cone is then gently placed into the Ball-Taper component, using the Insertion Rod, and carefully placed over the top of the X-pin onto the stem.

The Trial Humeral Heads can be used along with the Grub Screws in order to assess the correct size of humeral head needed.

Note

Care should be taken when trialing as the definitive Ball-Taper must NOT be damaged by the Grub Screws or Trial Heads, and the Expansion Cone must NOT be prematurely forced up into the definitive Ball-Taper.

The chosen humeral head is then inserted into the definitive Ball-Taper (with Expansion Cone already placed in the Ball-Taper). The humeral head is adjusted so that it covers the resection plane of the humerus. When the head is set parallel with the incision on the humerus and the head covers the resection plane in inclination, retrotorsion and offset, prefix the head to the Ball-Taper component using three consecutive defined impulses from the Impactor. The prefixed head component is now removed from the stem.

Note

Care should be taken to ensure that the Expansion Cone does not come out of the Ball-Taper. Before inserting the Set Screw, confirm that the Expansion Cone is in the Ball-Taper.

The Set Screw is inserted from the lower side of the head into the Ball-Taper component using the 4.5mm Nut. The Set Screw is then screwed loosely into the Ball-Taper component until it sticks.

The head implant is then set in the assembly tower and lightly fixed with the Threaded Rod. Connect the Torque Wrench to the 4.5mm Nut. The Set Screw is then fastened with the Torque Wrench, using the 4.5mm Nut, until it is tight. The head prosthesis has now been permanently fixed and can be carefully removed from the assembly block.

The X-pin is removed from the humeral stem using the 2.5mm Hex Screwdriver.

Note

Before the head prosthesis can be placed on the stem prosthesis, the cones must be carefully cleaned of blood and possible other residues.

The head prosthesis is now placed on the stem prosthesis, after appropriate rotation. The head prosthesis is then impacted onto the humeral stem with the Humeral Head Impactor.

Removal of the Implant Stem

The Humeral Stem Setting Instrument with Extractor is used if the humeral stem must also be removed after removal of the humeral head and reaming of the resection plane.

The Humeral Stem Setting Instrument is positioned on the cone of the stem (Fig. 68). The Humeral Stem Setting Instrument is fixed tightly on the humeral stem, using the Tightening Screw which is screwed into the thread of the stem. The Tightening Screw is tightened with the 5mm Hexagonal Wrench.

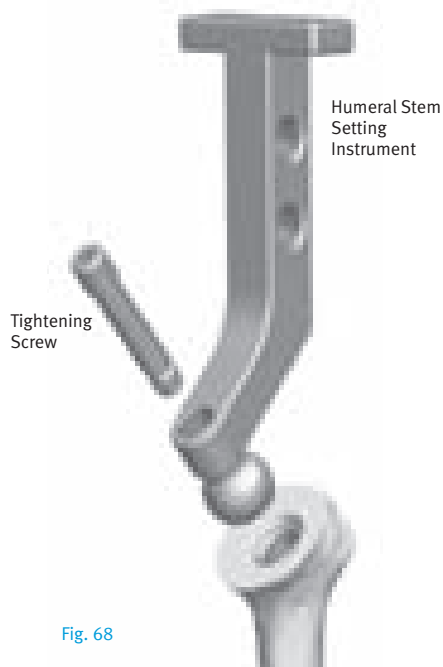


Fig. 68

The Extractor with Slide Hammer Weight can now be screwed onto the Humeral Stem Setting Instrument.

The implant stem is now removed from the humeral canal with energetic blows.

Note

If the Ball-Taper cannot be removed with the humeral head, a monoblock construct must be accepted. A readjustment of the humeral head on a humeral stem of this type is not possible; the implant stem must be fully removed.

The Milling Cutter is passed over the Ball-Taper, opening up a free position for applying the stem extraction instrument (Fig. 69).



Fig. 69

Reaming is performed using the Cannulated Handle from the glenoid tray.

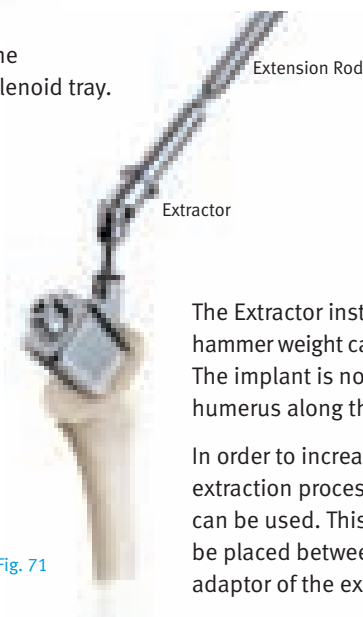

Fig. 71

The stem extraction construct consists of a Split Chuck, an Adapter and a Screw (Fig. 70).

This extraction construct is required for the removal of the humeral stem. The Split Chuck is first placed on the Ball-Taper. The Adapter is then placed over this Split Chuck. The Screw is tightened, resulting in a secure connection between the Split Chuck and the Adapter (Fig. 70).



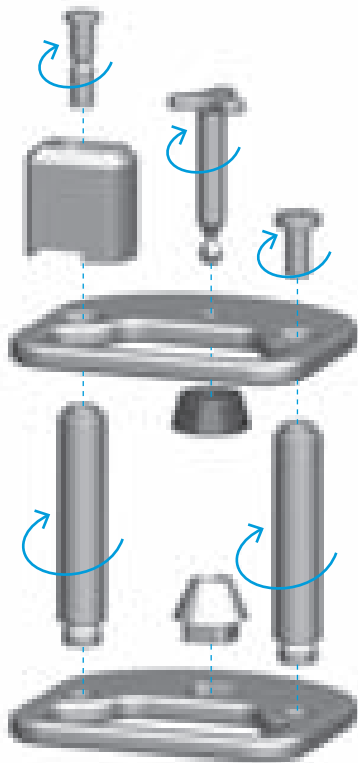
Fig. 70

The Extractor instrument with slap hammer weight can now be connected. The implant is now removed from the humerus along the shaft axis.

In order to increase the efficiency of the extraction process an extension rod can be used. This extension rod is to be placed between the handle and the adaptor of the extractor (Fig. 71).

Preparation and Description of the Assembly of the Instruments


Assembly block for the humeral head and stem



Either the Right Fracture Cone Holder or Left Fracture Cone Holder should be used in preparation for fracture care. (See “Special Version for Setting Fractures” on page 21).



Assembly and Disassembly of the Impactor



Charging the Impactor

Tense the Impactor with the help of the loading aid (Charger).

The Impactor is connected through the shaft of the Charger.

There are two possible procedures: Either the Charger is placed on the table (Fig. 72), or the Charger is held in one hand, the Impactor in the other (Fig. 73, 74), while the shaft of the Charger is inserted into the Impactor and tenses the Impactor.

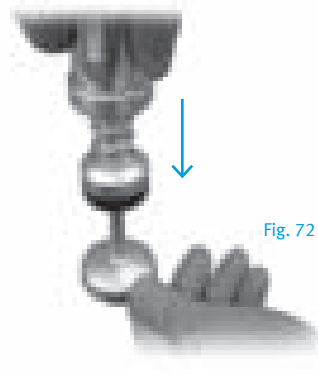


Fig. 72

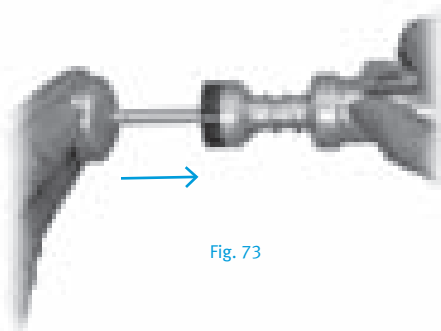


Fig. 73

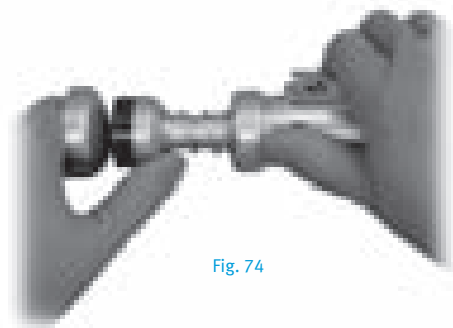




Fig. 74

Review of the Instrument Trays


Instrument Tray I
ANSH500



Instrument Tray II
ANSH600



Glenoid Trays




Pegged
ANSH0100



Keeled
ANSH0101



Revision Tray
ANSH700





Please refer to package insert for complete product information, including contraindications, warnings, precautions, and adverse effects.

Contact your Zimmer representative or visit us at www.zimmer.com

