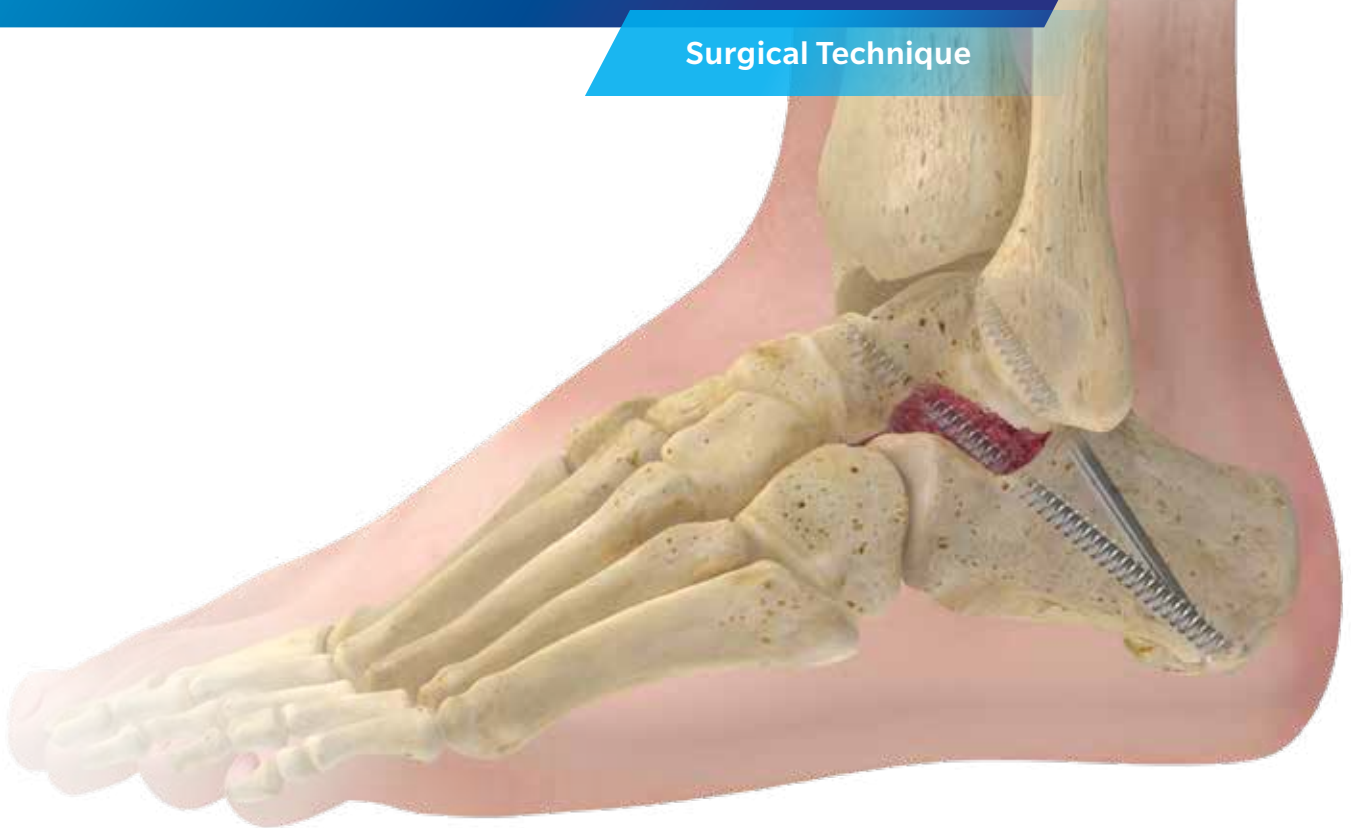

# Bone Grafting Technique for Foot and Ankle Applications: A Supplement

## Surgical Technique



Dr. Stuart Miller, MD  
Department of Orthopaedic Surgery  
MedStar Union Memorial Hospital  
Baltimore, Maryland

Zimmer Biomet does not practice medicine.  
This booklet was prepared in conjunction with  
a licensed surgeon experienced in bone grafting procedures.



# Table of Contents

- Introduction** ..... 2
- Bone Grafting Surgical Techniques**
  - 1st MTP Fusion with A.L.P.S.® Foot System ..... 3
  - Midfoot Fusion with A.L.P.S.® Foot System ..... 6
  - Evans Osteotomy with OsseoTi® Wedge ..... 8
  - Subtalar Arthrodesis with Cannulated Screw System ..... 12
  - Calcaneal Fracture with A.L.P.S.® Foot System..... 16
- Appendix A: Choice of Bone Graft Material**..... 18
- Appendix B: Bone Marrow Aspiration from the Calcaneus Technique**..... 20
- Appendix C: Product Catalog Numbers** ..... 24
- Product Indications and Contraindications** ..... 25
- References** ..... Back Cover

Comprehensive plating and screw systems are used to treat a variety of foot and ankle trauma and reconstruction procedures including: osteotomies, fusions, and fractures in the forefoot, midfoot, and hindfoot. The goal of this surgical technique supplement is to educate the reader on key surgical technique steps relative to the application of bone graft material in common foot and ankle procedures.

This surgical technique is intended to serve as a supplement to the A.L.P.S. Total Foot System, OsseoTi Porous Metal Foot and Ankle Reconstructive Wedges, and Cannulated Screws.

## 1st MTP Fusion with A.L.P.S. Foot System

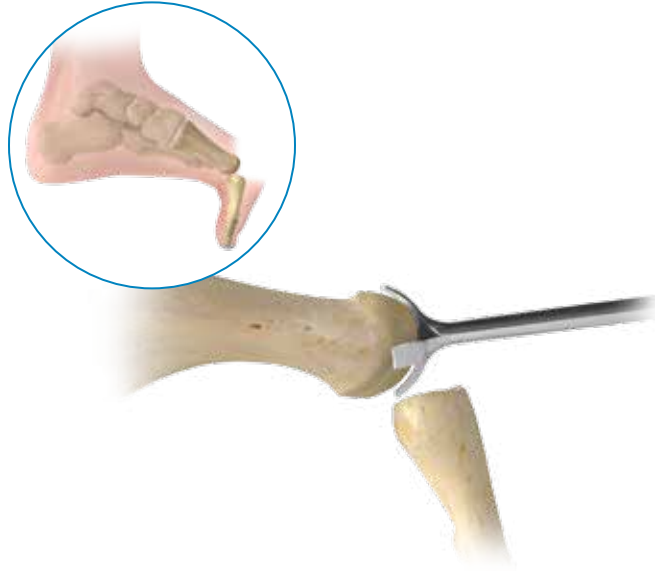


Figure 1

### Exposure and provisional fixation

Perform a longitudinal incision beginning just proximal to the interphalangeal joint and extend over the 1st MTP joint medial to the extensor hallucis longus. Expose the proximal phalanx and metatarsal head and denude all cartilage surfaces exposing the bleeding subchondral bone. If shortening of the metatarsal is a concern, place autograft or allograft within the arthrodesis site. Use a 1.6 mm K-wire to provisionally fix the joint at the desired angle. If an interfragmentary cross screw is used, position the guide wire prior to positioning the plate.

**Note:** Take care to protect the dorsomedial cutaneous nerve during the dissection and exposure.

### Plate Placement

If utilizing cup and cone reamers to prepare the joint, determine the appropriate size of cone reamer by placing it over the metatarsal head to ensure adequate coverage. Cup and cone reamers range from 14–24 mm in diameter and have an AO quick connect attachment. Place a 1.6 mm K-wire into the center of the metatarsal head and drive it proximally into the diaphysis.

Place the cone reamer over the K-wire and begin reaming until all cartilage has been denuded and bleeding subchondral bone has been exposed (Figure 1). Be sure to protect the soft tissue and sesamoids during this step.

## 1st MTP Fusion with A.L.P.S. Foot System

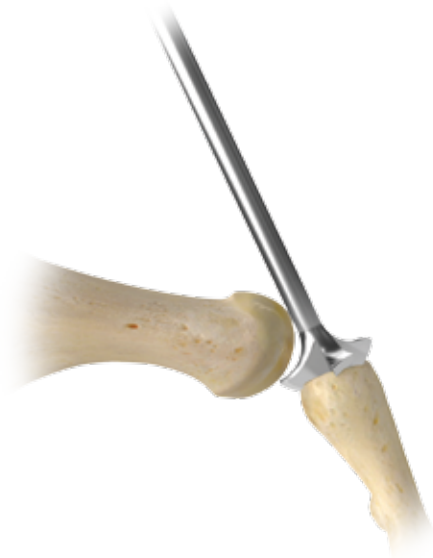

Figure 2

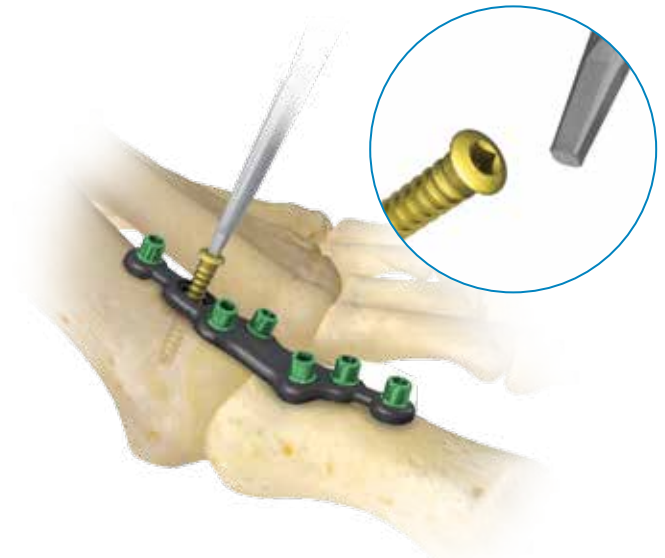


Figure 3

### Joint preparation

To prepare the joint surface of the phalanx, utilize the same size cup reamer as was used on the metatarsal for congruent surfaces. Insert a 1.6 mm K-wire into the center of the base of the proximal phalanx and drive it distally into the phalangeal diaphysis. Place the cup reamer over the K-wire and begin reaming until all cartilage is denuded and bleeding subchondral bone has been exposed (Figure 2).

⚠ **Caution:** To avoid excessive reaming, the reamers should be turning at slow speed prior to contact with the bone.

### Plate Placement

The plate should be placed dorsally such that it permits the placement of the screws adjacent to the joint line. Partially insert a 2.5 mm Non-Locking Screw through the oval hole of the plate to allow distal to proximal optimization of the plate (Figure 3). Some surgeons then place a lag screw across the joint while others use the plate to generate some compression. The remaining screws are placed in standard fashion.

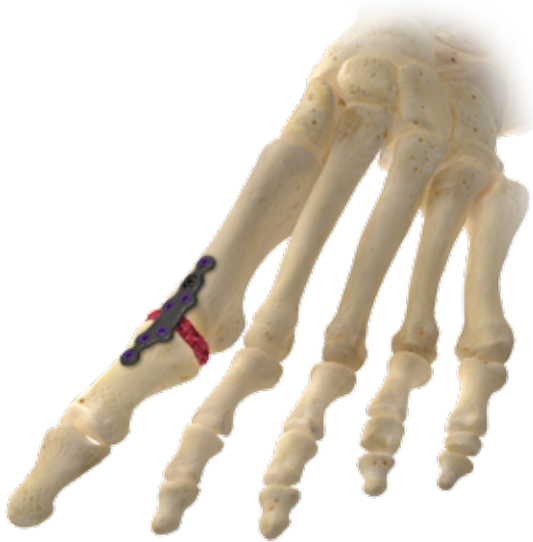

Figure 4

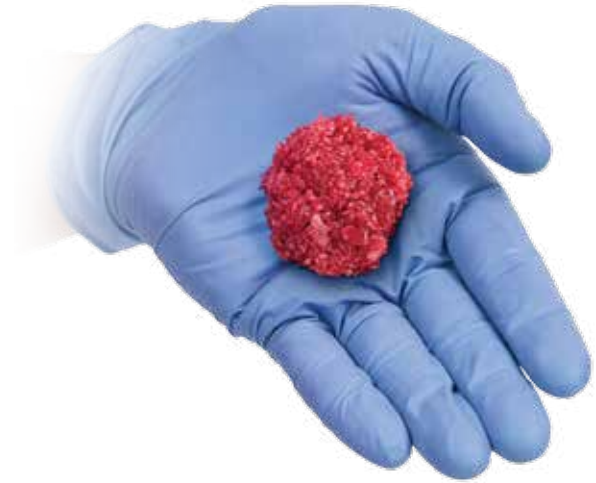

Figure 5

## Graft Insertion

Once the plate and screws are completely fixated, the hydrated graft material\* should be packed-in all along the joint line as well as alongside and when possible beneath the plate (Figure 4).

\* Bone graft material is prepared prior to application to the surgical site (Figure 5). Appendix A provides a brief guide to choosing a bone graft material. If hydration of bone graft material with BMA or PRP is desired, dispense the hydration fluid into a plastic cup on the sterile field. The bone graft material may be added to this cup and thoroughly mixed and saturated with the hydration fluid. Alternatively, the hydrating fluid may be taken up in a syringe and squirted directly on to the bone graft material.

## Midfoot Fusion with A.L.P.S. Foot System

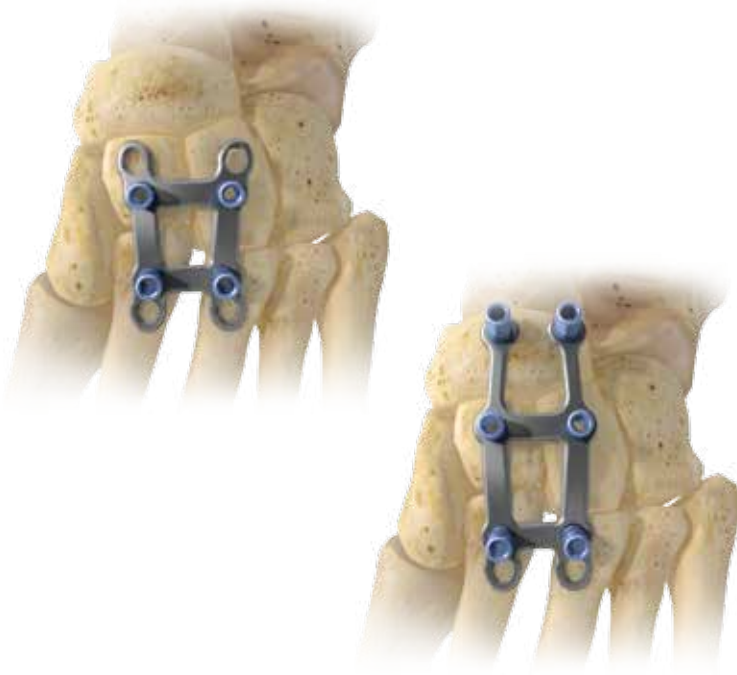

Figure 6

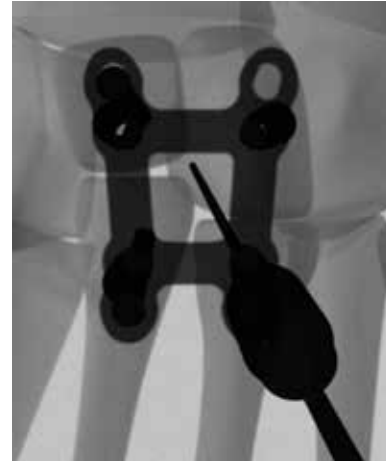

Figure 7

The following surgical technique applies to the fusion of the 2nd and 3rd tarsometatarsal joints. This general technique can also be applied to the fusion of the 1st and 2nd tarsometatarsal joints or for fixation of a Lisfranc fracture/dislocation.

### Exposure and Joint Preparation

Perform a longitudinal incision over the 3rd metatarsocuneiform joint. Expose the 2nd and 3rd metatarsocuneiform joints and denude all cartilage surfaces exposing the bleeding subchondral bone. To avoid shortening and elevation of the metatarsals place autograft or allograft within the arthrodesis site.

### Plate placement

Both the large and small Dorsal Midfoot Fusion plates are tapered proximal to distal, the widest segment should be positioned over the cuneiforms with the more narrow distal segment positioned over the metatarsals. Care should be taken to the plate such that the joint lines are located between the holes of the plate, to ensure screws are sufficiently clear of the joint line prior to screw insertion (Figure 6).

Suggestion: Using fluoroscopic guidance to the Small Dorsal Midfoot Fusion plate can be especially helpful to ensure adequate purchase of both the locking screws and compression screws in the cuneiform and metatarsal bones (Figure 7).

Using fluoroscopic guidance to the Large Dorsal Midfoot Fusion plate ensures that the navicular tabs are adequately centered within the navicular bone while maintaining proper alignment of the distal locking holes and compression slots within the 2nd and 3rd metatarsals.



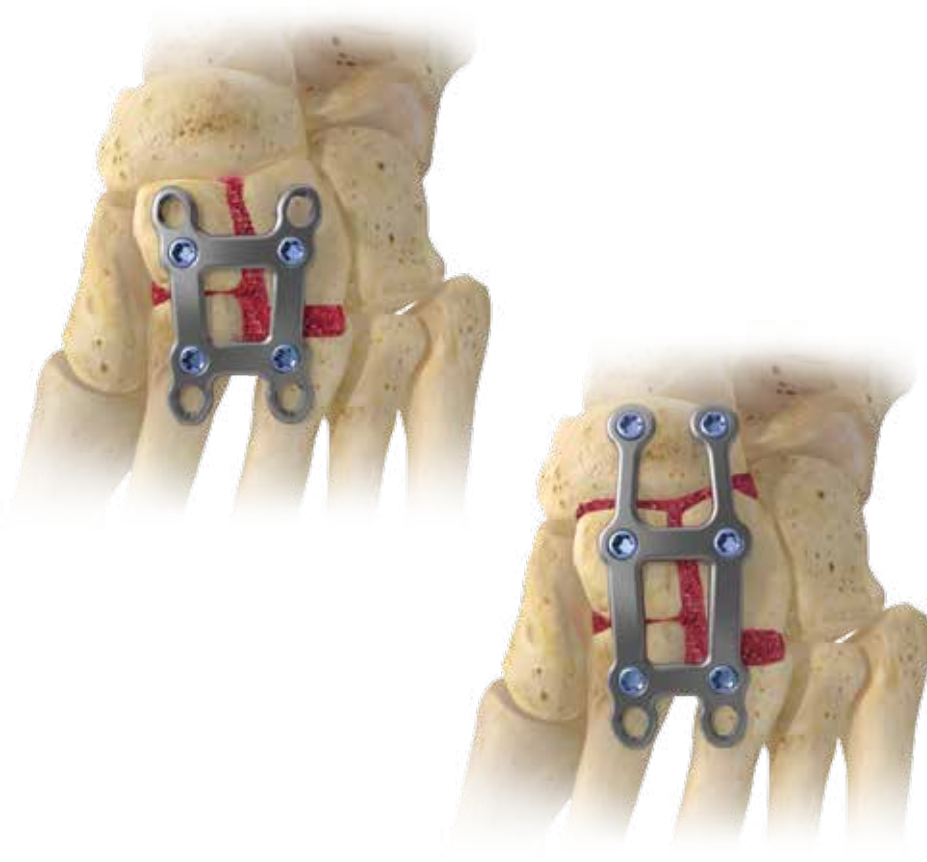

Figure 8

## Bone Graft

Once the plate and screws are completely fixated, the hydrated graft material\* should be packed-in all along the joint lines everywhere between the bones and when possible beneath the plate (Figure 8).

\*Refer to Page 5 for additional information on Bone Graft Material Preparation

## Evans Osteotomy with OsseoTi Wedge

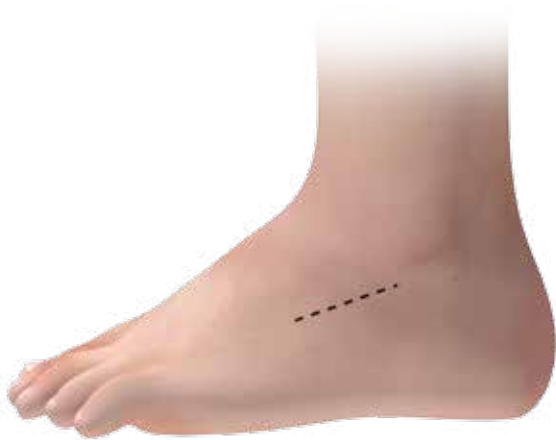

Figure 9

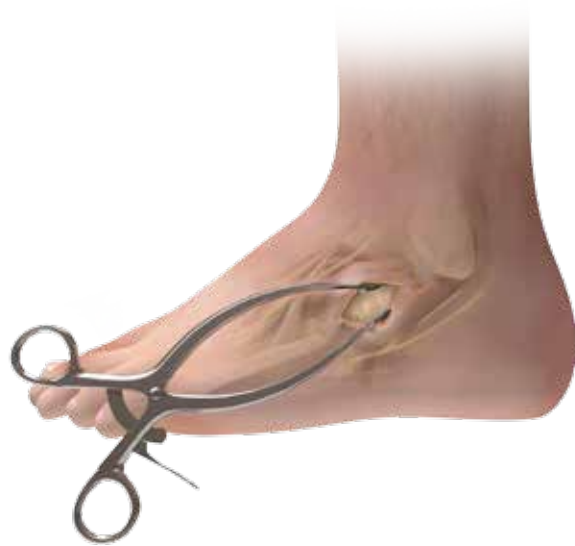

Figure 10

### Incision

Make an incision just below the sinus tarsi, extending laterally approximately 3 cm proximal to the calcaneal-cuboid joint (Figure 9).

### Exposure

Carefully reflect extensor digitorum muscle belly superiorly and retract the peroneal tendons along with the sural nerves inferiorly to expose the lateral calcaneal and calcaneocuboid joint (Figure 10).

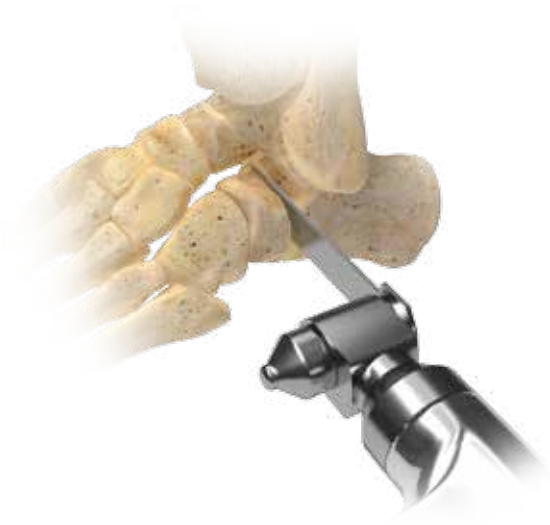

Figure 11

### Osteotomy cut

10–12 mm proximal to the calcaneocuboid make an osteotomy parallel to calcaneocuboid joint leaving the medial cortex intact (Figure 11).

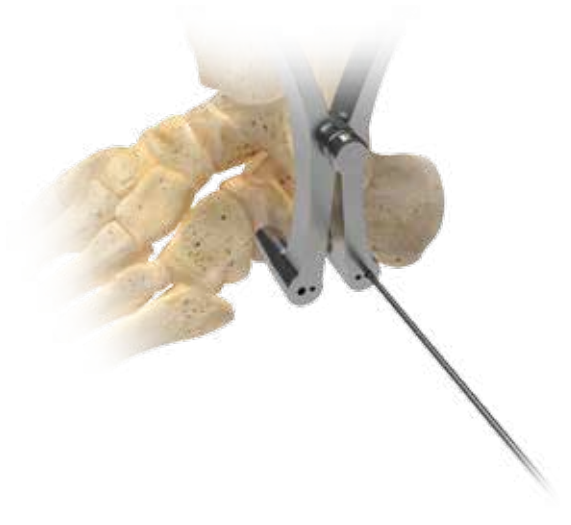

Figure 12

### Sizing

Surgeon has the option to utilize a distractor. Place a 2.0 mm (or 1.6 mm) Steinmann pin on each side of the osteotomy and utilize a distractor to aid in distraction and access to the osteotomy site (Figure 12).

Trials can help surgeon determine appropriate size of the OsseoTi wedge.

## Evans Osteotomy with OsseoTi Wedge




Figure 13

### Bone Graft

Pack hydrated graft\* into both openings of OsseoTi wedge prior to correct placement (Figure 13).

\*Refer to Page 5 for additional information on Bone Graft Material Preparation



Figure 14

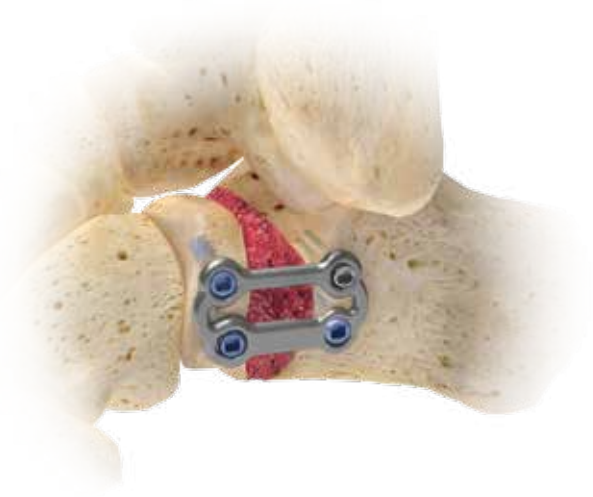

Figure 15

## Fixation

Ancillary fixation is required when using OsseoTi Reconstructive Wedges (Figure 14). Refer to the A.L.P.S. Total Foot Surgical Technique BMET0008.4 for a detailed protocol.

ⓘ **Note:** Hydrated graft can be used without OsseoTi wedges (Figure 15).

## Subtalar Arthrodesis with Cannulated Screw System

### Patient Preparation

The patient is placed in the supine [alternatively, some surgeons prefer a lateral position] position, with lateral tilting using a bean bag positioner, on a standard table. A tourniquet is usually applied on the proximal thigh and inflated to 300 mm Hg after preparation and draping. The patient should be given a general or spinal anesthetic prior to the procedure, usually augmented with a local block as well.

**Note:** For the purposes of this technique, we will discuss only the open technique and instrumentation as it relates to the 6.5 mm cannulated screw. However, the 8.0 mm cannulated screw may also be used in some large foot applications.

### Surgical Exposure

A lateral longitudinal incision is placed from the base of the fourth metatarsal to a spot just distal to the tip of the fibula. Sharp incision followed by dissecting scissors progresses just above the peroneus brevis tendon to the dorsal bone of the calcaneus. This approach usually creates an interval between the extensor digitorum brevis muscle and the peroneal tendon. In some instances the muscle needs to be split. Care is taken to avoid damage to sural nerve branches which should be more distal in most feet.

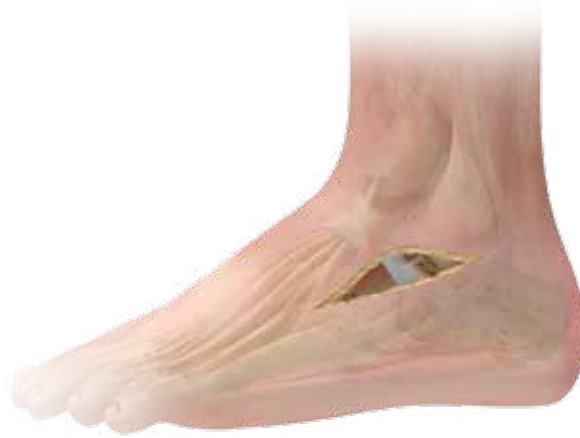

Figure 18

### Surgical exposure (cont.)

The brevis muscle and its fascia are lifted from the dorsal and lateral aspects of the calcaneus through sharp dissection. The sinus tarsi fat pad will similarly be lifted and allow exposure of the subtalar joint. The bifurcate ligaments should be released sharply (Figure 18). Once the ligaments are released, a lamina spreader can be inserted into the sinus tarsi to open the subtalar joint; a small Homan elevator laterally along the joint retracts soft tissues and helps with visualization.

### Joint Preparation

The cartilage is removed with a combination of a chisel and curettes. A thin curette blade can lift the cartilage and the curettes are used to remove any remaining cartilage. A larger curved curette proves useful for removing cartilage at the back of this curved “saddle” joint. With good preparation, the flexor digitorum longus tendon can often be seen in the posteromedial aspect of the joint; avoid plunging in front of this and damaging the tibial neurovascular bundle. After cartilage removal and irrigation, the subchondral bone should be disrupted and pierced with either a small 2.5 mm drill or a small osteotome to “shingle” the surface.

## Subtalar Arthrodesis with Cannulated Screw System

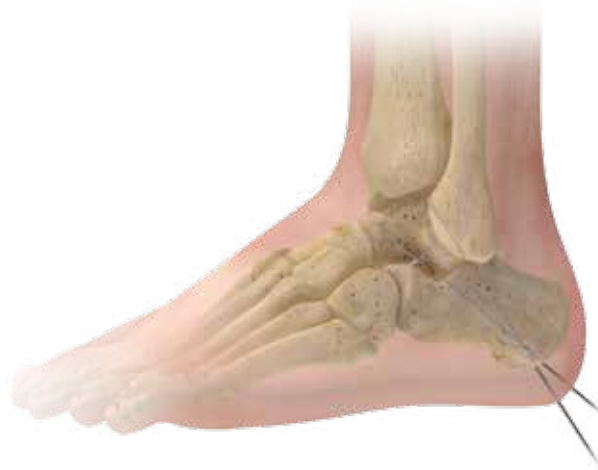

Figure 19

### Placement of the Guide Pins

A small stab incision should be made in the central heel to allow guide wire placement. The joint is reduced, usually to about 5 degrees of clinical valgus. The first 2.8 mm guide wire is placed from the posterior edge of the calcaneus to the talar dome, ending just in front of the tibia. The position should be checked on a small fluoroscopy unit to insure that it traverses the subtalar joint well and that it does not penetrate the talar dome surface. An AP ankle view can be useful to discern the appropriate positioning as lateral placement into the ankle gutter is a common mistake. A second guide wire is placed from the posterior calcaneus into the talar neck (Figure 19). This pin should be checked in multiple views to insure placement is in the middle of the talar neck and not traversing the talonavicular joint.

### Drilling

The first guide wire is measured for length. Connect the 4.8 mm cannulated drill to a power adapter and slide the drill over the guide wire. Drill to appropriate depth and remove drill, leaving the guide wire in place.

Repeat above for second screw placement.

ⓘ **Note:** Per surgeons preference, screws may or may not be countersunk.



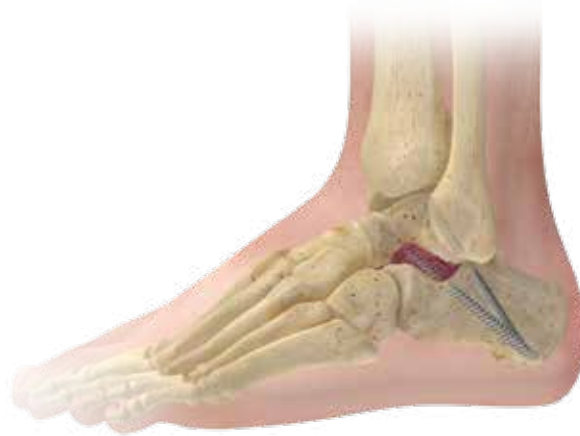

Figure 20

### Screw Insertion

The first screw inserted over the wire that goes from the calcaneus towards the talar dome. This will be a partially threaded screw to achieve compression across the posterior facet. Advance the partially threaded 6.5 mm screw over the guide wire using the BT30 cannulated hexalobular screwdriver until the head of the screw is completely seated in the bone.

Repeat above for second screw that goes into talar neck. Second screw can be partially or fully threaded per surgeon's choice.

### Bone Graft

Once the screws are completely fixated, the hydrated graft material\* should be packed-in all along the joint lines. The sinus tarsi space also offers further bone fusion opportunities and can be packed with the bone graft material (Figure 20).

\*Refer to Page 5 for additional information on Bone Graft Material Preparation

## Calcaneal Fracture with A.L.P.S. Foot System

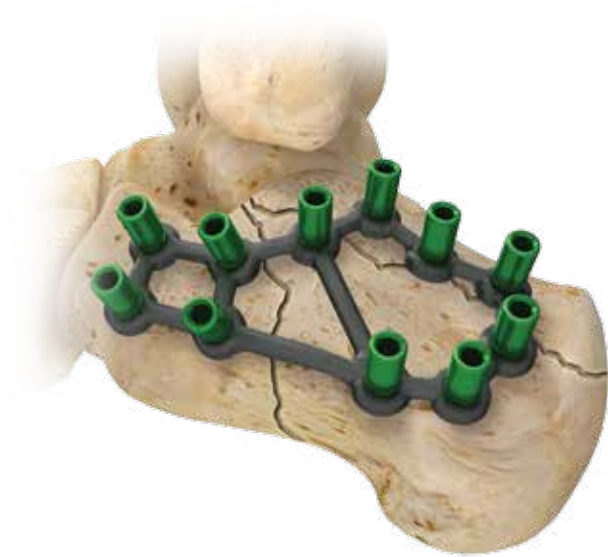


Figure 21

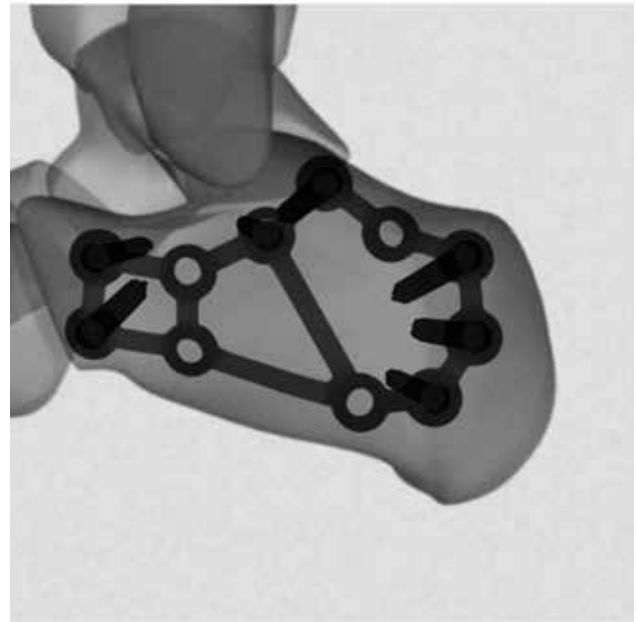


Figure 22

### Approach

The calcaneus is approached through an extensile lateral incision which minimizes the sequelae of peroneal tendinitis and devascularization of the anterior skin flap, as well as preserving the sural nerve which should be entirely within the flap. The calcaneo-fibular ligament is taken with the flap. The full thickness flap is then retracted using the “no touch” technique by the use of three K-wires, one up the fibular shaft, one in the talar neck and one in the cuboid. Next, a short Schanz pin is inserted into the calcaneus at posterior inferior corner of the wound to be used as a handle for subsequent reduction.

### Provisional fixation and reduction

A lateral longitudinal incision is placed from the base of the fourth metatarsal to a spot just distal to the tip of the fibula. Sharp incision followed by dissecting scissors progresses just above the peroneus brevis tendon to the dorsal bone of the calcaneus. This approach usually creates an interval between the extensor digitorum brevis muscle and the peroneal tendon, sometimes the muscle needs to be split. Care is taken to avoid damage to sural nerve branches which should be more distal in most feet.

### Plate fixation

Once reduction is verified, the plate is sized and positioned on the lateral surface such that the most superior F.A.S.T. Guide® insert lies just under the posterior articular facet and the most superior anterior F.A.S.T. Guide insert is positioned just in line with the anterior superior portion of the anterior articular facet (Figure 21). Final verification of plate size and placement is easily confirmed under fluoroscopy (Figure 22).

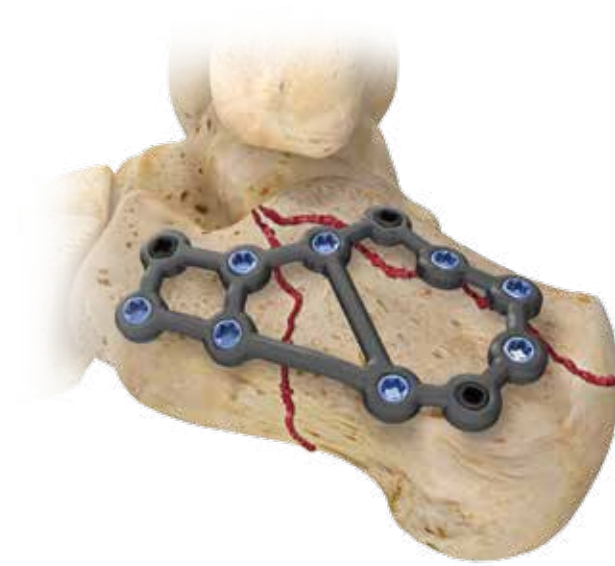


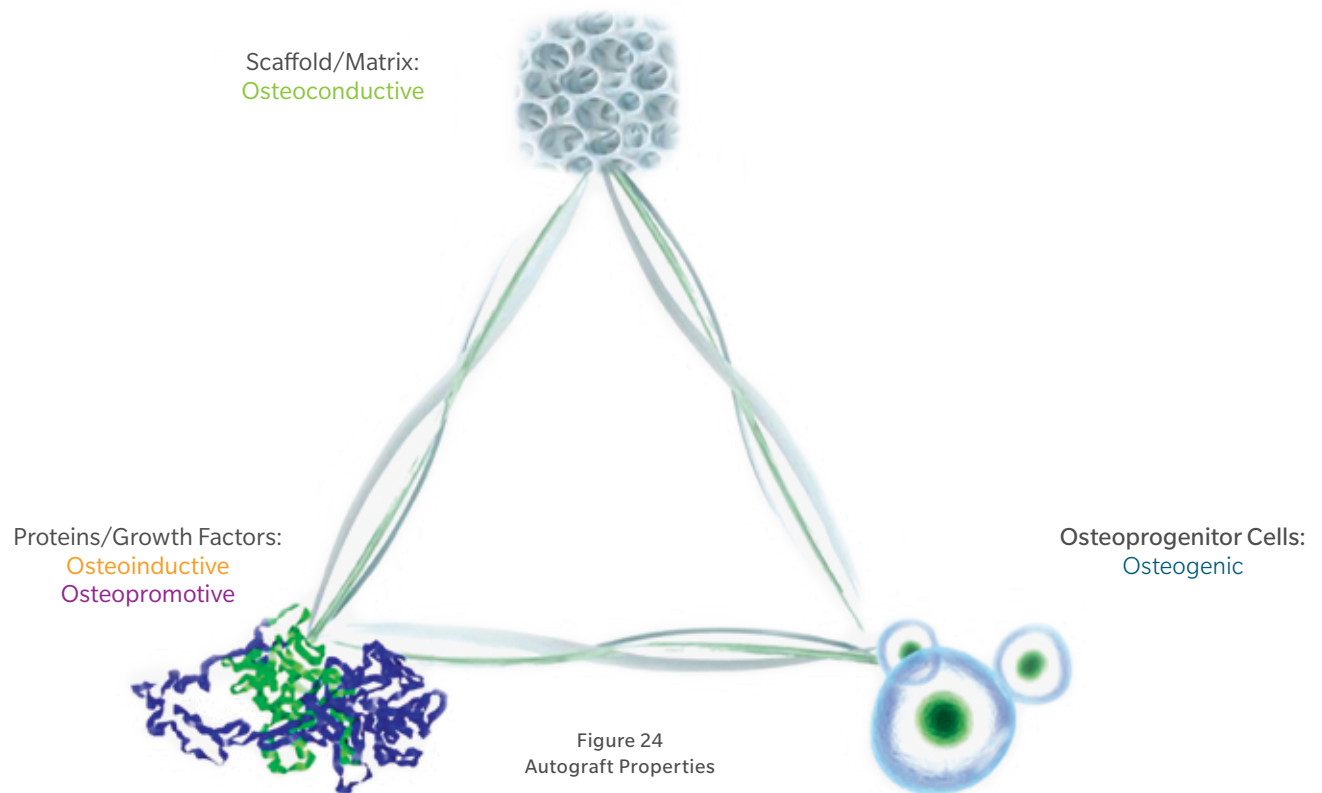
Figure 23

## Bone Graft

Once the screws are completely fixated, the hydrated graft material\* should be packed-in all along the joint line as well as alongside and when possible beneath the plate (Figure 23).

\*Refer to Page 5 for additional information on Bone Graft Material Preparation

## Appendix A: Choice of Material



### Choice of Bone Graft Material

Autograft is the most common bone graft material of choice for foot and ankle procedures.<sup>1</sup> Autograft is the gold standard because it has all the principal elements necessary to form a solid fusion.<sup>2,3</sup> Specifically, autograft not only contains the scaffolding necessary for bone healing, but it also is able to induce bone formation as it contains the pluripotential cells and signals necessary for successful bone healing<sup>2</sup> (Figure 24). Additionally, there is no risk of disease transmission.<sup>2</sup>

The use of autograft has some downsides including the increased surgical time and prolonged pain at the donor site.<sup>2</sup> This leads to the need for alternate solutions, such as synthetic and allograft/demineralized bone matrix (DBM) materials.

There are numerous bone graft material choices available for foot and ankle procedures today,<sup>2</sup> and they include DBM putties/gels, synthetic HA/Collagen materials combined with BMA, allograft/autograft combined with PRP, etc. Bone marrow aspirate (BMA) or platelet-rich plasma (PRP) can be combined with DBM particles and/or cancellous chips and used as a bone graft material, because the combination graft material exhibits osteoconductive, osteoinductive and osteopromotive properties.<sup>4-6</sup>

The use of blood or bone marrow aspirate with graft materials can provide platelets or mesenchymal cells at the procedure site.<sup>7</sup> Clinical evidence suggests cellular concentration may positively affect the clinical outcome of bone grafting procedures.<sup>8,9</sup>

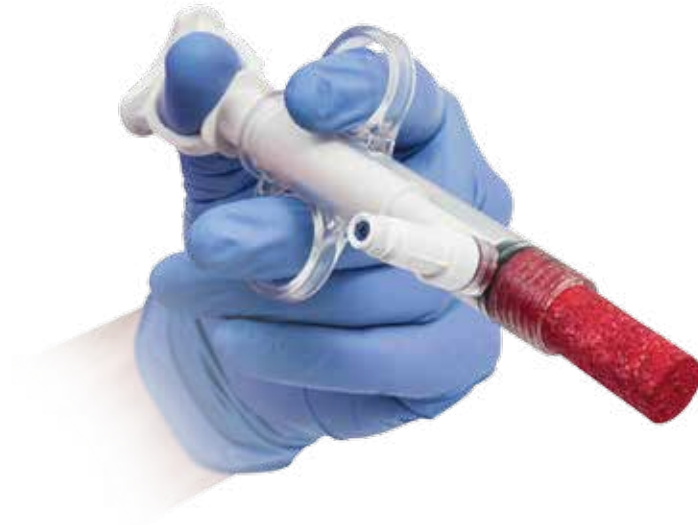

Figure 25

Bonus<sup>®</sup> CC Matrix is allograft bone. It is both osteoinductive and osteoconductive. These characteristics make it an attractive autograft alternative.

Bonus CC Matrix utilizes a unique formulation of demineralized cortical bone (DBM) and mineralized cancellous chips. This combination of optimal sizes and ratios provides a unique scaffold for bone growth while avoiding the common delivery and packing challenges associated with larger bone chips.

Bonus CC Matrix offers all the benefits of allograft while providing the surgeon a consistent and efficient method of hydration with PRP or BMA (see Figure 25).

The cortical bone (DBM) and mineralized cancellous chips used in Bonus CC Matrix come from the same donor. The tissue is processed using Allowash<sup>®</sup> technology to inactivate a broad panel of viruses. Potential donors are evaluated through a multi-step process and subjected to testing that meets current AATB and FDA requirements.

Allowash is a trademark of LifeNet Health Corporation.

## Appendix B: Bone Marrow Aspiration Prep from the Calcaneus Technique

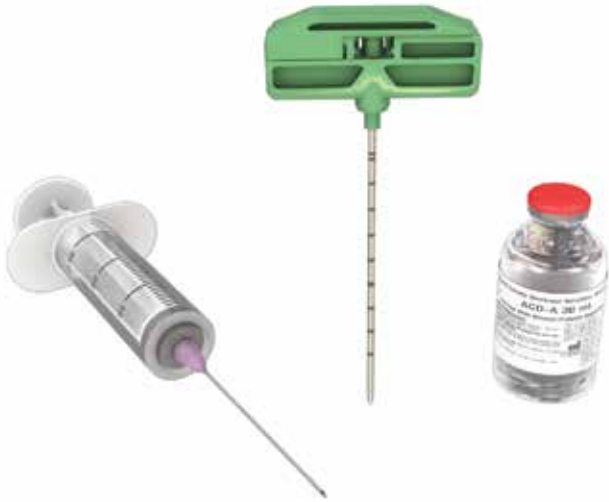

Figure 26



Figure 27

### Prep Materials

Bone marrow aspiration requires the following items:

- Scalpel (#15 blade works well)
- Mallet
- 30 ml syringe(s)
- Trocar needle and BMA cannula
- ACD-A (anticoagulant)

ⓘ **Note:** There are many types of BMA needles/cannulas on the market. In this technique, the Biomet BOS Bone Marrow Aspiration Kit (part no. 800-0705) is used for illustrative purposes.

### Prime with ACD-A (to prevent clotting)

Before the procedure, use a 30 ml syringe to draw the appropriate amount of ACD-A for the desired amount of bone marrow to be aspirated as well as any additional volume needed to prime the syringe and cannula (Figure 26). For aspirating bone marrow, ensure a 1:5 ratio of ACD-A to bone marrow.

#### Steps

- Detach and remove the trocar needle from the BMA cannula (Figure 27)
- Attach the syringe filled with ACD-A to the cannula handle
- Depress the syringe to allow ACD-A to flow through the cannula leaving enough for a 1:5 ratio of ACD-A to bone marrow
- Attach the trocar needle back onto the cannula handle

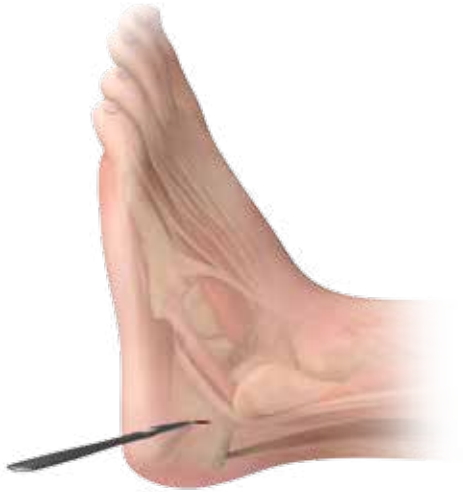

Figure 28

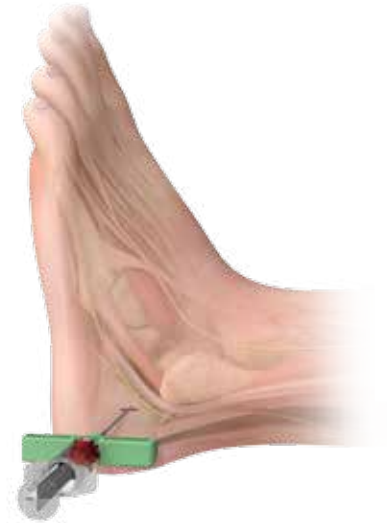

Figure 29

## Step Two: Needle Insertion

Make a small incision on the lateral side of the ankle, anterior to the insertion of the achilles tendon (Figure 28).

Insert the BMA needle anterior to the Achilles tendon and posterior to the sural nerve (Figure 29).

- ⊖ **Note:** The insertion point may vary based on an individual patient's anatomy.
- ⊖ **Note:** The tourniquet must not be engaged as lack of blood flow will limit aspiration of bone marrow and blood.

## Appendix B: Bone Marrow Aspiration Prep from the Calcaneus Technique

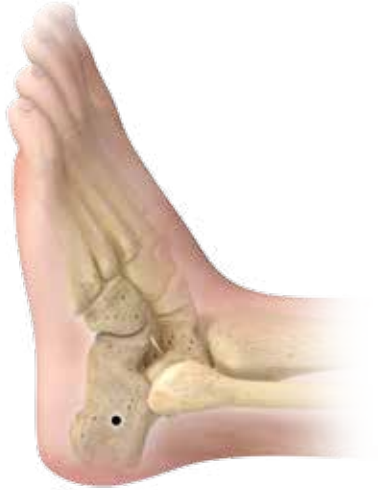

Figure 30

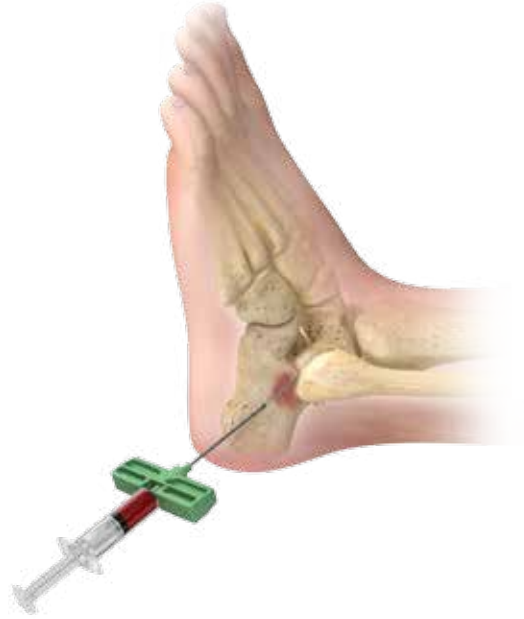

Figure 31

### Step Two: Bone Marrow Aspiration (cont.)

Using the same insertion point (Figure 30), up to three passes can be made through the calcaneus. For each pass, position the BMA needle at a maximum depth within the cancellous bone.

Advance the trocar medial and dorsal to the insertion point. Insert the needle to a maximum depth of 3cm or until resistance from cortical bone on the side opposite the insertion point is met.

Aspiration: Remove the trocar and connect the anticoagulated syringe to the BMA needle. Aspirate 2–4 ml of bone marrow. Withdraw the needle 1cm and repeat the aspiration. Continue this while the end of the BMA needle is positioned in cancellous bone (Figure 31).



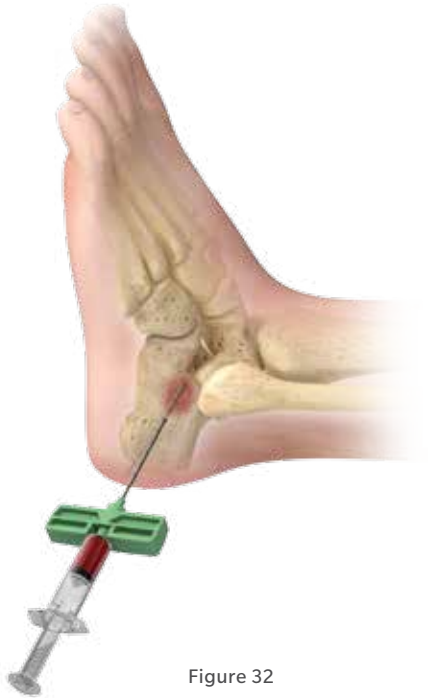

Figure 32

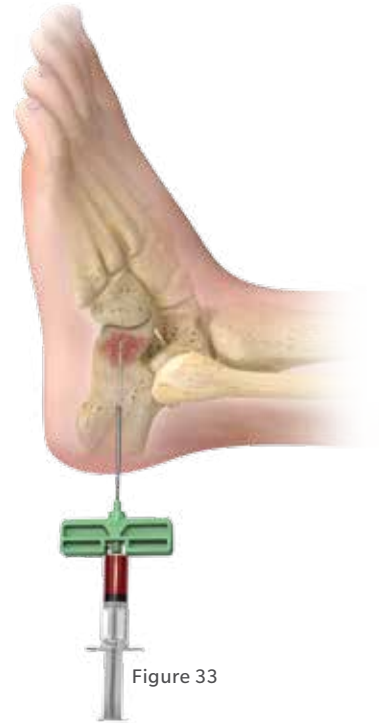

Figure 33

## Step Two: Bone Marrow Aspiration (cont.)



Advance the trocar anterior to the first pass towards the sustentaculum tali. Insert the BMA needle to a maximum depth of 5cm or until resistance from cortical bone on the side opposite the insertion point is met. Perform aspiration as described above (Figure 32).

Advance the trocar toward the calcaneocuboid joint. Insert the BMA needle to a maximum depth of 5cm or until resistance from cortical bone on the side opposite the insertion point is met. Perform aspiration as described before (Figure 33).

## Appendix C: Product Catalog Numbers - BioCUE

Product	Description	Part Number
	<b>BioCUE® βBMA Concentration System Kit (Standard)</b>	800-0611a
	<b>BioCUE βBMA Concentration System Kit (Mini)</b>	800-0610a
	<b>Bone Marrow Aspirate Needle</b>	800-0705
	<b>Bone Graft Convenience Kit with BioCUE Standard Disposable</b>	800-0536
	<b>Bone Graft Convenience Kit with BioCUE Mini Disposable</b>	800-0534

## Appendix C: Product Catalog Numbers

Product	Description	Part Number
	Bonus <sup>®</sup> CC Matrix – 5cc	48-1805
	Bonus CC Matrix – 10cc	48-1810

## Product Indications and Contraindications

### BONUS CC MATRIX

#### INDICATIONS

Bonus CC Matrix can be used to fill bony voids or gaps that have been surgically created, or for filling osseous defects in nonweight bearing applications. Bonus CC Matrix may be used with orthopedic, spinal, reconstructive, craniofacial, maxillofacial and periodontal bone grafting procedures. It can be used alone or in combination with autologous bone, or other forms of allogeneic bone in grafting procedures of non-weight bearing value. It can be used or hydrated with autologous blood, bone marrow aspirate, or autologous blood derived products such as platelet-rich plasma and platelet-poor plasma. It may also be hydrated with saline or antibiotic solution.

#### CONTRAINDICATIONS

Infection at the surgical site and/or distant foci of infections that may spread to the surgical site is a contraindication for Bonus CC Matrix.

### BIOCUE $\beta$ BMA CONCENTRATION SYSTEM

#### INDICATIONS

The BioCUE  $\beta$ BMA Platelet Concentration System Concentration System is designed to be used in the clinical laboratory or intraoperatively at the point of care for the safe and rapid preparation of platelet-poor plasma (PPP) and platelet-rich plasma (PRP) from a small sample of a mixture of blood and bone marrow. The plasma and concentrated platelets produced can be used for diagnostic tests. Additionally, the PRP can be mixed with autograft and/or allograft bone prior to application to an orthopedic site.

The PRP prepared by this device has not been evaluated for any clinical indications.

## References for Appendix A

1. US Markets for Orthopedic Biomaterials 2014, RPUS200B13, Table 32, p. 78, Millennium Research Group, November 2013.
2. Whitehouse MR, *et al*, Bone Graft Harvest from the Proximal Tibia in Foot and Ankle Arthrodesis Surgery. *Foot & Ankle International*. 2006; 27(11):913-916.
3. Jahangir *et al*, Bone-Graft Substitutes in Orthopaedic Surgery, *AAOS Now*, Jan. 2008.
4. Gandhi *et al*, The Role of Platelet-Rich Plasma in Foot and Ankle Surgery, *Foot Ankle Clin N Am*, 10 (2005) 621– 637.
5. Lewandrowski *et al*, *Advances in Spinal Fusion – Molecular Science, Biomechanics and Clinical Management*, p. 384-385, Marcel Dekker, Inc., 2004.
6. Watson, *Overview of Biologics*, *J Orthop Trauma*, Vol. 19 No 10 Suppl, Nov./Dec. 2005.
7. Jia *et al*, The Use of Platelet-Rich Plasma in the Management of Foot and Ankle Conditions, *Oper Tech Sports Med*, 19:177-84, 2011.
8. Muschler *et al*, Selective retention of bone marrow-derived cells to enhance spinal fusion, *CORR*, 432: 242–51, 2005.
9. Hernigou, *et al*, Percutaneous Autologous Bone-Marrow Grafting for Nonunions: Influence of the Number and Concentration of Progenitor Cells, *JBJS*, 87:1430-1437, 2005.

All content herein is protected by copyright, trademarks and other intellectual property rights owned by or licensed to Zimmer Biomet or its affiliates unless otherwise indicated, and must not be redistributed, duplicated or disclosed, in whole or in part, without the express written consent of Zimmer Biomet.

This material is intended for health care professionals and the Zimmer Biomet sales force.

Distribution to any other recipient is prohibited. For complete product information, including indications, contraindications, warnings, precautions, and potential adverse effects, see the package insert and [www.zimmerbiomet.com](http://www.zimmerbiomet.com). See also product-specific brochures and surgical techniques for product shown, herein, available through your local distributor.

This technique was prepared in conjunction with Stuart D. Miller, M.D.

Zimmer Biomet does not practice medicine. The treating surgeon is responsible for determining the appropriate treatment, technique(s), and product(s) for each individual patient.

©2016 Zimmer Biomet



**ZIMMER BIOMET**

Your progress. Our promise.™



**Legal Manufacturer**  
Biomet Orthopedics  
P.O. Box 587  
56 E. Bell Drive  
Warsaw, Indiana 46581-0587  
USA

[www.zimmerbiomet.com](http://www.zimmerbiomet.com)

0310.1-US-en-REV0316