

PerFuse Percutaneous Core Decompression Instrumentation

Femoral Head Surgical Technique



Table of Contents

- Core Decompression Background 2**
- Instrumentation Overview 3**
- Instrumentation Assembly 4**
- Patient Preparation..... 5**
- Biologic Preparation 6**
- Instrumentation Introduction 7**
- Biologic/Graft Delivery 9**
- Part Numbers..... 11**

This surgical technique was prepared in conjunction with Dr. Stephen Fern, M.D. Biomet Biologics, as the manufacturer of the PerFuse Percutaneous Decompression System, does not practice medicine and does not recommend this or any other surgical technique for use on a specific patient and is not responsible for the kind of treatment selected for a specific patient. The treating surgeon is responsible for determining the appropriate treatment, technique(s), and product(s) for each individual patient.

Avascular Necrosis (AVN)

Avascular necrosis (AVN) of the femoral head is a disease commonly associated with corticosteroid use, alcohol abuse, trauma, and sickle cell disease.

The young to middle-aged patient population necessitates a joint-preserving procedure that prevents or postpones an unadvisable total joint arthroplasty.¹⁻³ This is especially critical for patients with sickle cell disease, as 90% of those with AVN experience femoral head collapse within two years of diagnosis and also tend to have higher failure rates and more complications with arthroplasty.⁴ Avascular necrosis is the result of disruption of the vascular supply to the bone tissue.⁵

Clinical Benefits of Biologically-Assisted Core Decompression

1. 86% see significant reduction of pain¹⁷
2. Disease progression is stopped in 77%-94% of patients after multi-year follow-up¹⁸⁻²⁵
3. Lesion size reduced in 82% of patients and 16% of those observed complete resolution of lesion²⁰

Table 1

Core Decompression

Core Decompression is a surgical technique to treat early detected Avascular Necrosis involving drilling one or more channels into the dead bone (necrotic lesion). Creating a channel into the necrotic lesion is intended to relieve intraosseous pressure within the bone and provide a channel to restore blood flow to the diseased bone.^{6,7} Often, core decompression involves the removal of a plug of bone out of a necrotic lesion.

Alternatively, bone decompression can be performed without the removal of a plug of necrotic tissue. The core decompression creates local autograft at the tip of the cannula in the necrotic lesion, and an internal support scaffold is preserved by leaving the surrounding bone structure intact.

Core decompression has been demonstrated to lower pressure in the affected bone. This step can decrease pain in some patients presenting with Stage 1 or Stage 2 AVN.⁸⁻¹² Unfortunately, historically this procedure has been shown to be successful in only 50% of the patients.¹³⁻¹⁶ Many of these patients progress to femoral head collapse, fracture, or THA.

Biologically-Assisted Treatments

Multiple approaches have been employed to augment core decompression with various biological materials. Autologous bone marrow aspirate,¹⁷⁻²⁰ synthetic bone graft substitutes,^{21,22} and allograft products including milled trabecular bone²³ and vascularized fibular grafts^{24,25} have demonstrated clinical benefits to patients diagnosed with early stage AVN (Table 1).

The PerFuse Approach

Recently though, a new emerging technique is increasingly used during core decompression. This technique utilizes a 6 mm cannula which allows for easy backfilling while remaining small enough to allow immediate post-op weight-bearing. This is achieved without creating heat like a reamer, which could negatively impact the clinical result.²⁶



Figure 1

Instrumentation

The PerFuse Percutaneous Decompression System is designed to access the femoral head for decompression. The PerFuse cannula creates a 6 mm bore diameter channel into the necrotic tissue. This small diameter allows the PerFuse System to be used in small joints as well.

The instrument set is comprised of a single-use disposable kit containing:

- the cannula
- trocar rod
- plunger

and a reusable set containing:

- the reusable handle
- slide hammer
- slide hammer adapter
- strike cap

All components are made from ASTM F899 stainless steel.

The large (295 mm length) cannula, trocar rod, and plunger rod are designed to access and decompress necrotic tissue within the femoral head.

The shorter instrumentation (161 mm length) is designed to access and decompress necrotic tissue within the humeral head or other small joints.

Each cannula has lines etched onto the surface to indicate the instrument depth to the operating surgeon.



Figure 2



Figure 3

Assembly

Step 1: Fully seat the disposable PerFuse cannula into the PerFuse handle's quick connect.

Step 2: Introduce the PerFuse disposable trocar through the PerFuse handle and cannula (Figure 2).

Step 3: Tighten the screw cap on the back of the handle to lock the trocar in place (Figure 3). The PerFuse instrument is now fully assembled.

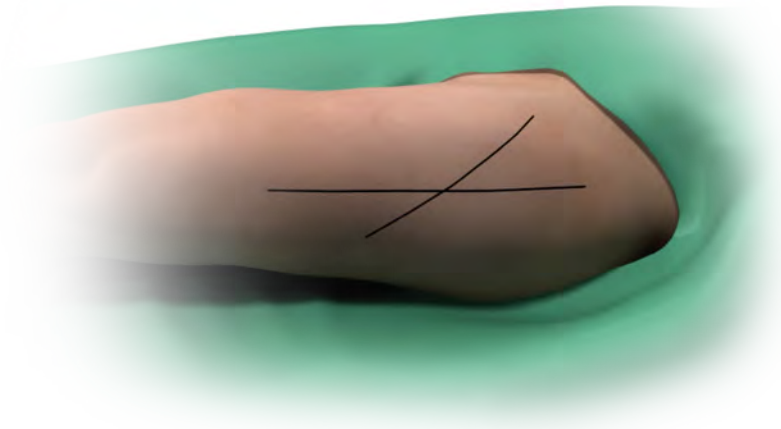


Figure 4

Patient Preparation

Prep OR with a fracture table. At times a fracture table maximizes imaging consistency and options. A second option is to place the patient in supine position on a radiolucent table.

Drape the patient in a manner that allows anterior-posterior (AP) and frog-leg radiographic images for instrument orientation. With the assistance of imaging, the PerFuse cannula is placed over the skin to determine the AP skin markings. A lateral image is also obtained by referencing the PerFuse cannula radiographically. This will provide landmarks for the lateral skin mark. The intersection of these skin markings is the incision location (Figure 4).

The hip (or hips) and the iliac crest (or crests for bilateral treatment) are prepped and draped following appropriate sterile field protocols.

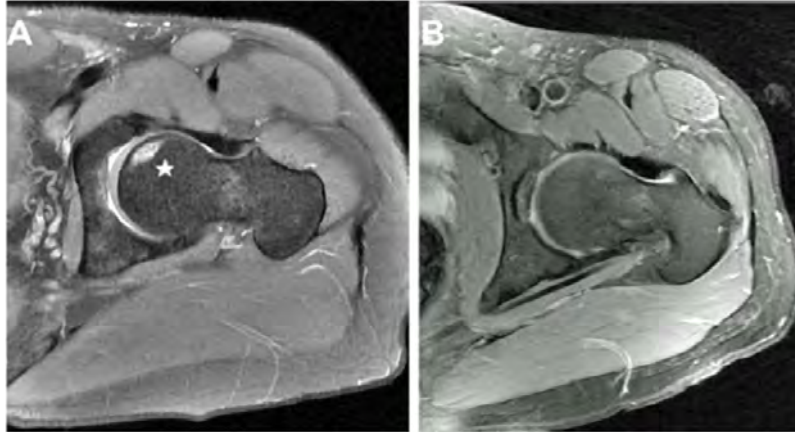

Image A. Preoperative MRI of a femoral head avascular necrosis lesion.

Image B. Follow-up MRI image two years post minimally invasive core decompression with injection of autologous BMA.

Figure 5

(Image reprinted with permission, Dove Medical Press LTD.)

Biologics Preparation

Biologically assisted core decompression with allograft, autograft, or synthetic bone graft material may be desired. The PerFuse system is designed to facilitate mixing and pre-mixing of bone graft material with I.V. fluids, blood, plasma concentrate, platelet-rich plasma, bone marrow or other specified blood components deemed necessary by the clinical use requirements.

Autograft Option: After the patient is positioned, draw 60-180 cc of a whole blood and bone marrow aspirate mixture. The whole blood and bone marrow aspirate are injected into BioCUE *BBMA* Concentration System* tubes. These tubes are processed for 15 minutes in a centrifuge. Each BioCUE tube produces a 6 cc PRP output, which should be prepped for delivery into the PerFuse cannula for hydration of local autograft bone.

Allograft Option: The PRP can be mixed with the allograft bone of choice on the sterile field. At that time the bone graft mixture can be prepped for delivery into the PerFuse cannula.

ⓘ **Note:** The graft material must be sized to fit through the cannula's 3.9 mm internal diameter.

*The BioCUE *BBMA* Concentration System is an accessory device. Please see the BioCUE package insert (also available www.biomet.com) for complete instructions for use.

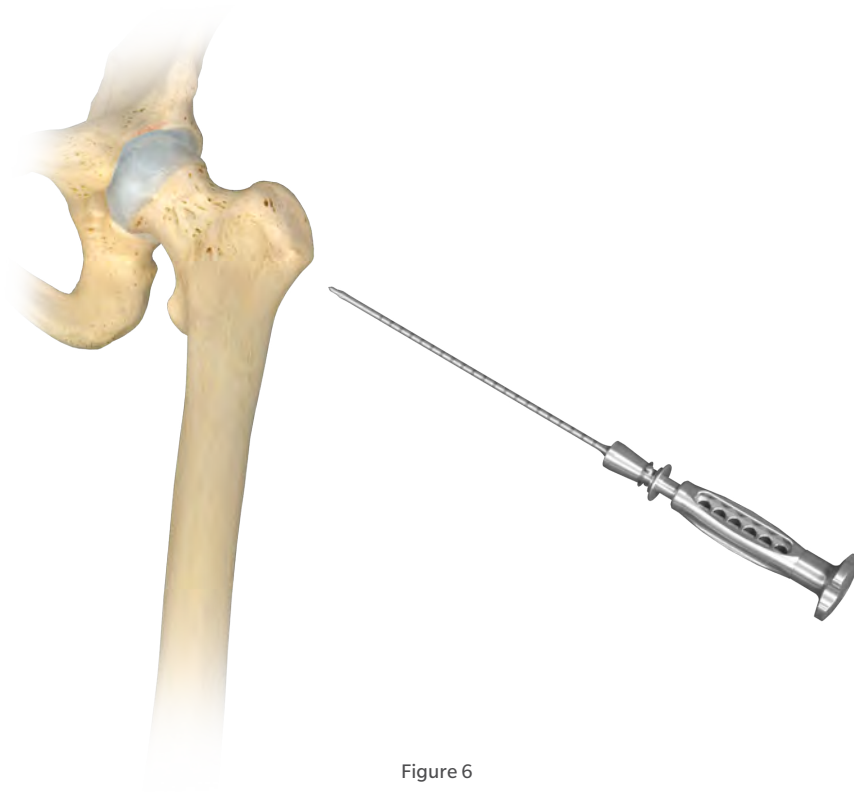


Figure 6

Incision

The position should be confirmed by fluoroscopy. Instrument orientation should be marked on the patient's skin. This marking will act as a visual guide during the PerFuse Instrument insertion (Figure 4).

A 1 cm incision is made over the lateral aspect of the femur just below the vastus ridge of the trochanter. The starting point is maintained proximal to the level of the lesser trochanter and distal to the vastus ridge.

ⓘ **Note:** Typically power instruments are not necessary except if entry into the lateral cortex is difficult.

Core Decompression Orientation

When the ideal starting point has been obtained the trocar is advanced from lateral to medial under biplanar fluoroscopy. Take care to verify the trocar position as the tip needs to be positioned parallel with the neck while stopping in the necrotic tissue (Figure 6). Altering the orientation of the PerFuse should be done prior to the cannula reaching 1 cm in depth. Also, if excessive force is needed to advance the trocar through the cortical bone the orientation of the instrument should be reassessed.

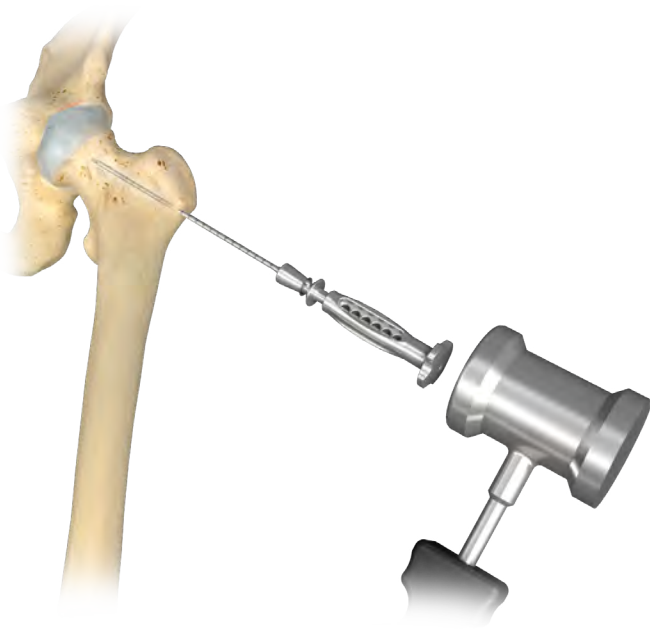


Figure 7

Advancing Instrument into Femur

Advance the instrument into the necrotic lesion by malleting the PerFuse Instrument Strike Cap. Typically, a change in mallet ping pitch is noted when the trocar has reached the area of necrosis. The areas of necrosis can be entered with the trocar, but should not be advanced within 5 mm of subchondral bone cortex to avoid collapse (Figure 7, 7a, and 7b). More caution should be taken when approaching an eccentric lesion.

This position is confirmed under biplanar fluoroscopy.

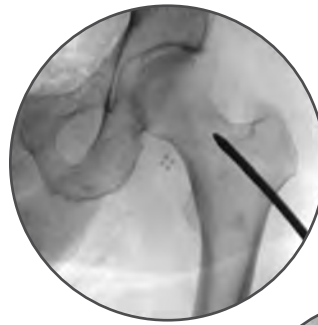


Figure 7a

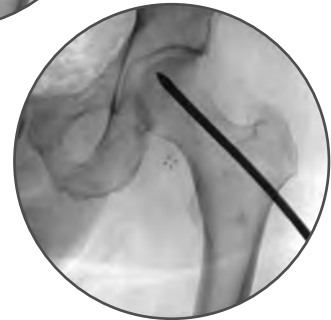


Figure 7b

Remove Instrument Handle and Prep for Bone Grafting Delivery

Separate the handle and trocar from the cannula by engaging the quick release. Keep the 6 mm cannula in the necrotic portion of the femoral head.

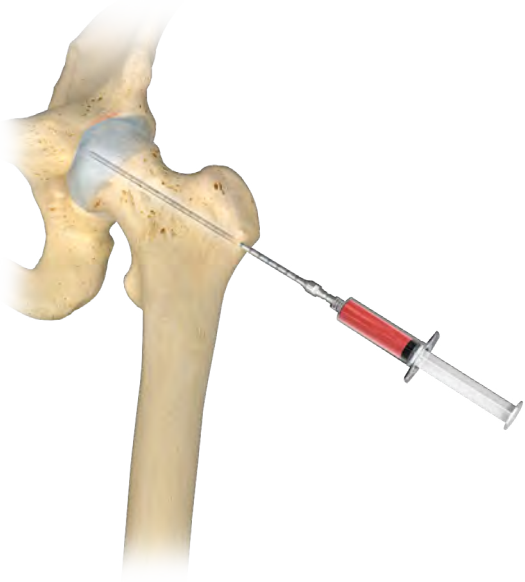


Figure 8

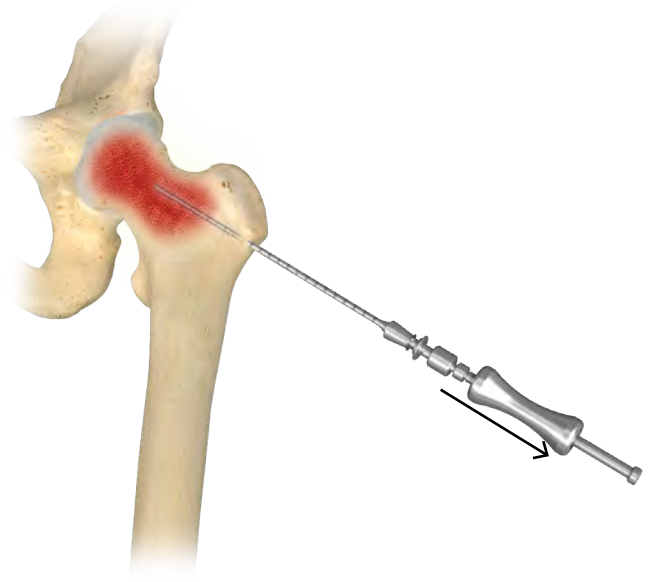


Figure 9

Biologic/Graft Delivery

Use the luer-lock to attach the 30cc syringe containing PRP or the chosen bone graft mixture to the PerFuse disposable cannula. Inject the contents into the necrotic tissue. Due to the sclerotic nature of the lesions, it may require significant pressure to complete this injection. If excessive resistance is met, the cannula can be retracted to a more lateral aspect of the necrotic tissue. This will increase the space for the injection and lower the pressure needed.

Remove syringe and advance the tamp until fully seated against the back of the cannula to express any remaining bone graft from the cannula.

Instrument Removal

If possible, manually remove the cannula. If a mechanical advantage is needed, the PerFuse Slide Hammer can be used to aid removal. To assemble, thread the Slide Hammer into the screw cap of the reusable handle.

The Slide Hammer assembly can also be attached directly to the cannula after the reusable handle has been removed via the Slide Hammer Adapter.

Please note, when the Slide Hammer is attached to the Slide Hammer Adapter, ensure the bell end of the Hammer faces away from the Slide Hammer Adapter to prevent interference from the adapter.

Note: The Slide Hammer Adapter's locking mechanism is engaged by attaching the cannula and rotating the quick release sleeve clockwise - counter-clockwise.

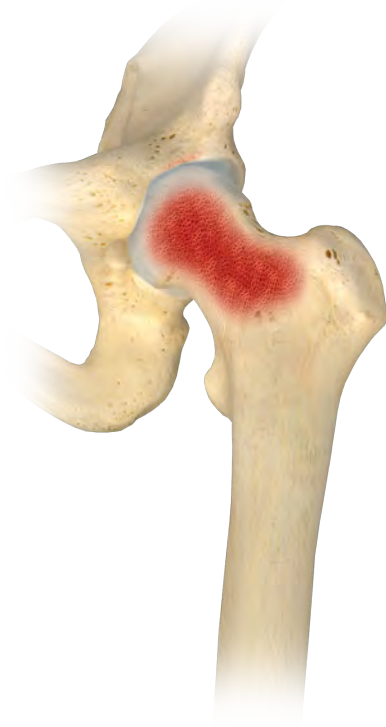

Figure 10


Final Look

The bone graft mixed with the output from the BioCUE β BMA Concentration System immediately permeates the femoral head and other necrotic tissues.

PerFuse Part Numbers

Product	Part Number	Description
	800-0541	Hip Disposable Instrument Set
	800-0542	Shoulder Disposable Instrument Set
	800-0543	Slide Hammer Adapter
	800-0544	Handle Strike Cap
	800-0545	Handle
	800-0546	PerFuse Instrument Case
	31-473621	Slide Hammer

Accessory Part Numbers

Product	Part Number	Description
	800-0611A	BioCUE β BMA (Blood and Bone Marrow Aspirate) Concentration System
	800-0610A	BioCUE Mini β BMA (Blood and Bone Marrow Aspirate) Concentration System

Loaner System Part Numbers

Part Number	Description
959-300	PerFuse Instrument Loaner Set: Slide Hammer Adapter (Qty 1) Slide Hammer (Qty 1) Handle Strike Cap (Qty 2) Handle (Qty 2) Instrument Case (Qty 1)
959-600	PerFuse Implants Loaner Set: Hip Disposable Instrument Set (Qty 3) Shoulder Disposable Instrument Set (Qty 3)

References

1. CureResearch.com. Statistics by country for Avascular Necrosis. 2010. Health Grades, Inc. 5-19-2014.
2. Drescher W, Pufe T, Smeets R, Eisenhart-Rothe RV, Juger M, Tingart M. [Avascular necrosis of the hip-diagnosis and treatment]. *Zeitschrift für Orthopädie und Unfallchirurgie* 2011; 149(2):231-240.
3. Ibrahim V, Dowling H. Platelet-rich plasma as a nonsurgical treatment option for osteonecrosis. *PM R* 2012; 4(12):1015-1019.
4. Kaushik AP, Das A, Cui Q. Osteonecrosis of the femoral head: An update in year 2012. *World journal of orthopedics* 2012; 3(5):49.
5. Amanatullah DF, Strauss EJ, and Di Sesare PE. Current management options for osteonecrosis of the femoral head: Part 1, diagnosis and nonoperative management. *Am J Orthop* 2011; 40(9): E186-192.
6. Mont MA and Hungerford DS. Non-traumatic avascular necrosis of the femoral head. *J Bone Joint Surg Am* 1995; 77(3):459-474.
7. Van Laere C, Mulier M, Simon JP, Stuyck J, Fabry G. Core decompression for avascular necrosis of the femoral head. *Acta Orthop Belg* 1998; 64(3): 269-272.
8. Fernandes M. Therapeutic Autologous Concentrated Bone-Marrow Grafting for the Repair of Early Femoral Osteonecrosis. 2013.
9. Marker DR, Seyler TM, Ulrich SD, Srivastava S, Mont MA. Do modern techniques improve core decompression outcomes for hip osteonecrosis? *Clinical Orthopaedics and Related Research* 2008; 466(5):1093-1103.
10. Steinberg ME, Larcom PG, Strafford B *et al.* Core decompression with bone grafting for osteonecrosis of the femoral head. *Clin Orthop Relat Res* 2001;(386):71-78.
11. Yan Z, Hang D, Guo C, Chen Z. Fate of mesenchymal stem cells transplanted to osteonecrosis of femoral head. *J Orthop Res* 2009; 27(4):442-446.
12. Yoshioka T, Mishima H, Akaogi H, Sakai S, Li M, Ochiai N. Concentrated autologous bone marrow aspirate transplantation treatment for corticosteroid-induced osteonecrosis of the femoral head in systemic lupus erythematosus. *Int Orthop* 2011; 35(6):823-829.
13. Koo KH, Kim R, Ko GH, Song HR, Jeong ST, Cho SH. Preventing collapse in early osteonecrosis of the femoral head. A randomised clinical trial of core decompression. *Journal of Bone & Joint Surgery, British Volume* 1995; 77(6):870-874.
14. McGrory BJ, York SC, Lorio R, *et al.* Current practices of AAHKS members in the treatment of adult osteonecrosis of the femoral head. *J Bone Joint Surg Am.* 2007; 89(6):1194-1204.
15. Von Stechow D, Drees P. Surgical treatment concepts for femoral head necrosis [in German]. *Orthopade.* 2007; 36(5):451-457.
16. Steinberg ME. Core decompression of the femoral head for avascular necrosis: indications and results. *Can J Surg.* 1995; 38(suppl 1):S18-S24.
17. Martin J, Houdek M, Sierra R. Use of concentrated bone marrow aspirate and platelet rich plasma during minimally invasive decompression of the femoral head in the treatment of osteonecrosis. *Croat Med J.* 2013; 54:219-24.
18. Martin J, Sierra R, Camp C. MRI Lesion Size and Prednisone Use Predict Success After Simple Head Decompression and Injection of Autologous Bone Marrow Concentrate. Mid-America Orthopaedic Association 31st Annual Meeting, April 17-21, 2013. Amelia Island, FL.
19. Hernigou P, Beaujean F. Treatment of Osteonecrosis With Autologous Bone Marrow Grafting. *Clinical Orthopaedics and Related Research* 2002; 405:14-23.
20. Hernigou P, Poignard A, Zilber S, and Rouard H. Cell Therapy of hip osteonecrosis with autologous bone marrow grafting. *Indian J Orthop.* 2009 Jan-Mar; 43(1): 40-45.
21. Civinini R, De Biase P, Carulli C, Matassi F, Nistri L, Capanna R, Innocenti M. The use of injectable calcium sulphate/calcium phosphate bioceramic in the treatment of osteonecrosis of the femoral head. *Int Orthop.* 2012; 36(8):1583-1588.
22. Aarvold A, Smith JO, Tayton ER, Jones AMH, Dawson JI, Lanham S, Briscoe A, Dunlop DG, Oreffo ROC. A tissue engineering strategy for the treatment of avascular necrosis of the femoral head. *Surgeon* 2013; 11(6):319-325.
23. Bertrand T, Urbaniak JR, Lark RK. Vascularized fibular grafts for avascular necrosis after slipped capital femoral epiphysis: is hip preservation possible? *Clin Orthop Relat Res.* 2013; 471(7):2206-2211.
24. Kawate K, Yajima H, Sugimoto K, Ono H, Ohmura T, Kobata Y, Murata K, Shigematsu K, Kawamura K, Kawahara I, Maegawa N, Tamai K, Takakura Y, Tamai S. Indications for free vascularized fibular grafting for the treatment of osteonecrosis of the femoral head. *BMC Musculoskelet Disord.* 2007; 8:78.
25. Devadasan B, Hafiz A, Harichandra D. Core decompression with reverse bone graft technique and hydroxyapatite granules in avascular necrosis of the femoral head. *Bone Joint J.* 2013; 95(B) Supp 15:163.
26. Harsanyi L. Scanning electron microscopy of heat-damaged bone tissue [in Hungarian]. *Morphol Igazsaguyi Ory Sx.* 1977 Feb; 17(1): 26-32.


All content herein is protected by copyright, trademarks and other intellectual property rights owned by or licensed to Biomet Inc. or its affiliates unless otherwise indicated, and must not be redistributed, duplicated or disclosed, in whole or in part, without the express written consent of Biomet.

This material is intended for health care professionals and the Biomet sales force. Distribution to any other recipient is prohibited.

For complete product information, including indications, contraindications, warnings, precautions, and potential adverse effects, see the package insert and www.Biomet.com.

©2017 Zimmer Biomet



 **Responsible Manufacturer**
Biomet Biologics
P.O. Box 587
56 E. Bell Drive
Warsaw, Indiana 46581-0587
USA