

The Uses of the F³[®] Fragment Plating System in the Foot and Ankle

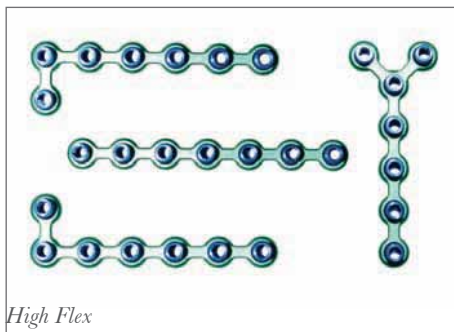
Mark Myerson, M.D.

*The Institute for Foot and Ankle Reconstruction at Mercy Medical Center
Baltimore, Maryland*

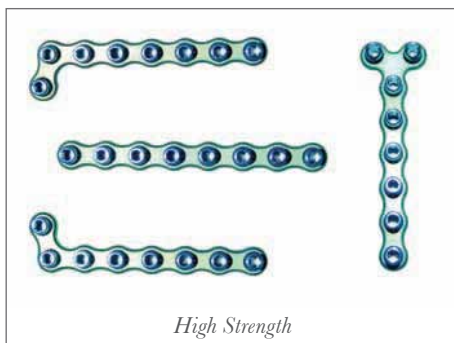
Introduction:

Plate fixation of a fracture, osteotomy or arthrodesis of the foot needs to be versatile, precise and adaptable to the local anatomy. Due to the marked variation in the structure of each metatarsal as well as the metatarsocuneiform and metatarsophalangeal joints, the plates need to have a varied shape, while maintaining flexibility and strength where needed.

The array of plates available with the F³ Fragment Plating system meets the needs described above. There are two basic types of plates, High Flex and High Strength, both of which have a locking screw capacity. (Figure 1) This locking screw technology provides a very stable construct in poor bone, although both locking and non-locking screws are available for each plate.



High Flex



High Strength

Figure 1: The array of F³ Plates are demonstrated, all of which are available either as a High Strength or High Flex.

Each plate hole has Fixed Angle Screw Targeting guides (F.A.S.T. Guides[®]), facilitating drilling and in situ bending of the plate. (Figure 2) These locking screw guides provide a source for leverage, so that both the High Flex and High Strength plates can be contoured and bent in both the axial and coronal plane, while affixed to the bone.

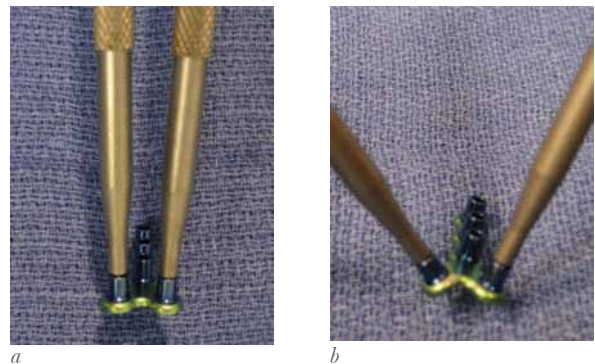


Figure 2: The pin end of each of the benders is demonstrated here inserted into the drill guides for contouring in the coronal plane (a,b).

The High Flex plate can also be bent in the sagittal plane. (Figure 3) The plate can be initially fastened to the bone, and then contoured, or may be bent initially to allow for insertion into a concavity as for example at the neck of the metatarsals.



Figure 3: High Flex plates allow for Sagittal Bends.

Plate cutters can easily trim the High Strength and the High Flex plates, although the benders can also be used to bend the High Flex plate up and down until it breaks. (Figure 4)

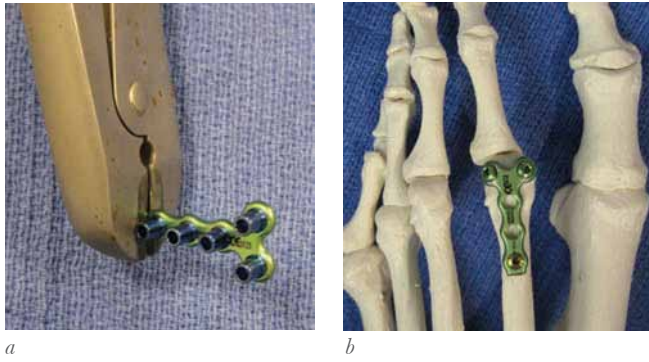


Figure 4: The length of the F³ plate is easily prepared with plate cutters (a). This is a versatile plate to use for the lesser metatarsal head as shown in (b).

Fractures and Non-Unions of the

Lesser Metatarsals:

Fractures of the lesser metatarsals associated with comminution are difficult to fix, particularly if they are intra-articular. The alternatives for fixation include longitudinal K-wires introduced axially in a retrograde manner from the toes across the MP joint and into the metatarsal. While this may be effective with fractures of the metatarsal neck, diaphyseal and more proximal fractures require more stable fixation. The more significant problem with the use of K-wires however is these need to cross the MP joints and in doing so, create stiffness of the joint which can be minimized with a low profile plate. Either the High Strength or the High Flex plates can be used in these cases. If comminution is present at the base of the metatarsal with articular preservation, then a Y-plate or L-plate can be used to span across the joint into the cuneiform or cuboid until healed, when the plate can be removed. Due to the paucity of motion at the 2nd and 3rd tarsometatarsal joints, and if the patient is asymptomatic, the plate may be left in situ following this treatment.

Plate Fixation of the 1st Metatarsal:

In general, fixation of the 1st metatarsal can be successfully accomplished with screws for various osteotomies, and small and mini fragment plates for fixation of fractures. However, there are situations where these methods of fixation are not sufficient, nor meet the anatomic requirements for stable metatarsal fixation. One important application of the F³ plating system is for fixation of osteotomies where standard screw fixation has failed, whether this is a Ludloff, proximal chevron, scarf or base closing wedge osteotomy. This typically occurs in patients with osteopenia, or where complications of screw fixation such as metatarsal fracture

or fragmentation occur. The advantage of the F³ plating system is its ability to adapt to the medial or dorsal surface of the 1st metatarsal base, particularly with a Y or L-shaped plate. (Figure 5 and 6)

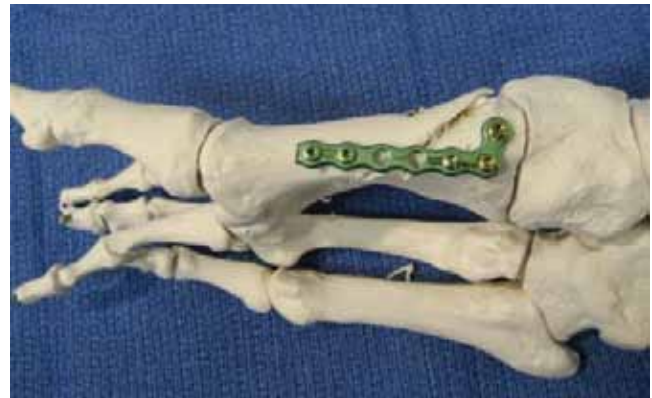

Figure 5: This model demonstrates the application of a High Strength F³ plate along the medial surface of the 1st metatarsal to supplement screw fixation of a Ludloff osteotomy. The plate can be bent in the coronal plane to add to the stability of correction of the metatarsal.

This patient underwent a Ludloff 1st metatarsal osteotomy and bunionectomy for correction of hallux valgus. Intraoperatively, a fracture of the dorsal surface of the 1st metatarsal occurred and stability of the fixation was lost. This was corrected with a medially applied L-shaped F³ plate with an excellent result. (Figure 6)

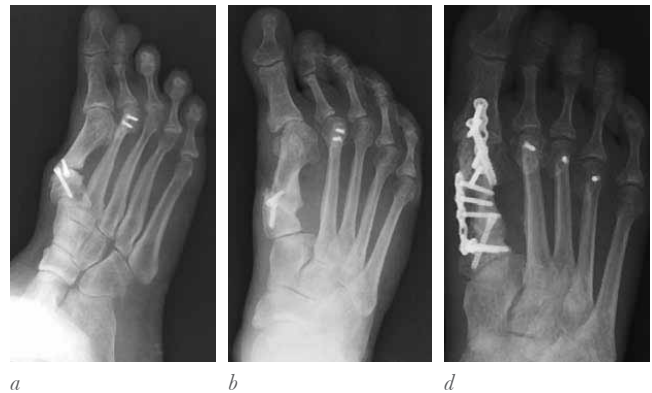
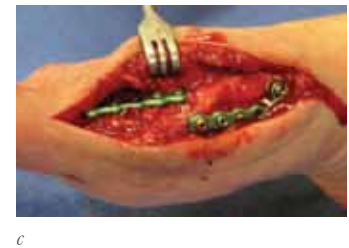
Figure 6: This is the pre-operative (a,b), intra-operative (c), and post-operative images of a patient with very complex forefoot deformity following failed prior 1st metatarsal osteotomy for correction of hallux valgus deformity. Arthritis of the hallux MTP joint is present associated with hallux varus and a fixed extension deformity of the hallux. There is in addition a non-union of the proximal osteotomy. This was corrected with an arthrodesis of the hallux MP joint using a 4.0 mm cannulated screw, supplemented with a straight High Strength plate. The proximal non-union was repaired and secured with an angled High Strength plate (c) with excellent healing and alignment (d). Revision of the 2nd metatarsal osteotomy, with additional osteotomies of the 3rd and 4th metatarsal with small twist off screws was performed.



Tarsometatarsal Case A:

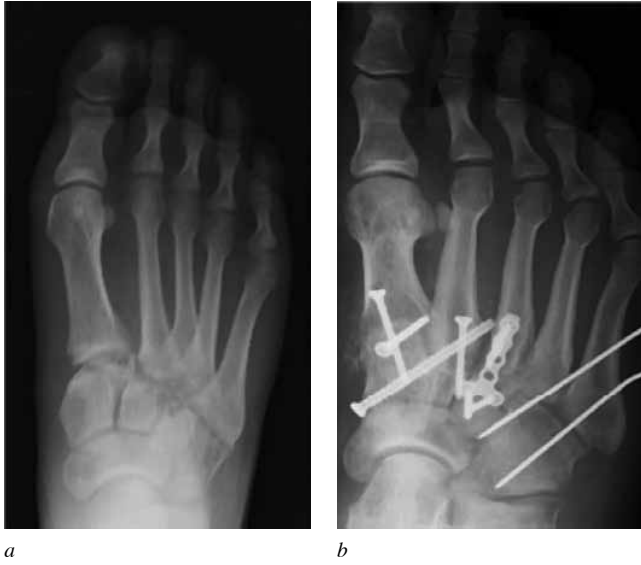

Figure 7: A good indication for the use of a small flexible plate is at the base of the 2nd or 3rd tarsometatarsal joint in the setting of joint comminution and fragmentation. Here is a patient with a fracture dislocation of the tarsometatarsal joint complex (a) which was treated with primary arthrodesis of the 1st, 2nd and 3rd joints. Although screws were comfortably used across the 1st and 2nd joints, there was significant comminution of the 3rd metatarsal base and the lateral cuneiform, and a High Strength Y-plate was used to achieve arthrodesis.(b)

Tarsometatarsal Case B:

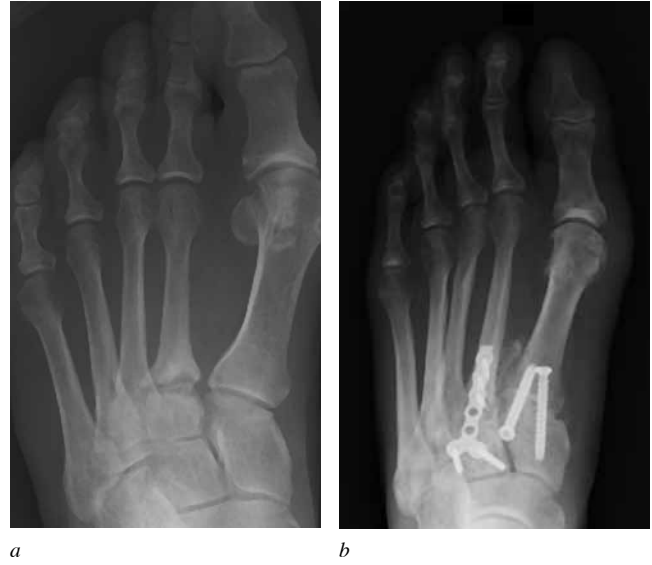

Figure 8: This patient had a complex hallux valgus deformity associated with hypermobility of the 1st metatarsal and a chronic non-union of the base of the 2nd metatarsal associated with painful arthritis of the 2nd tarsometatarsal joint.(a) The hallux valgus was corrected with a Lapidus procedure using 4.0 mm cannulated screws, and the non-union and the 2nd TMT joint were simultaneously corrected with a High Strength Y-plate.(b)

The Tarsometatarsal Joint(s):

Due to the low profile and the limited surface area of the joint, it can be difficult to secure the 2nd and in particular the 3rd tarsometatarsal joints. The articulation of the 1st tarsometatarsal joint is larger and generally can easily be secured and compression obtained using 3.5 mm or 4.0 mm screws. However, arthrodesis of the 2nd and 3rd joints are not as easy, due to the vertical triangular shape of the joint, and the difficulty with insertion and compression with screws. Frequently these joints are sclerotic, and following joint preparation, large gaps are present in the articulation which require bone graft and secure, stable fixation. If there is hypertrophy of the base of the joint with dorsal osteophytes, screws may be easier to insert, using the enlarged base of the 2nd metatarsal and cuneiform to insert one compression screw. Although staples may be considered in these joints, the fixation obtained is never secure, and only one staple can be safely used without increasing the risk of fracture. A small contoured plate is ideal in this location, particularly in the setting of arthritis or fracture with comminution. A High Strength plate is an excellent choice for the lesser tarsometatarsal joints, since it can be gently contoured into flexion which will compress the articulation with fixation. (Figure 7 and 8)

All trademarks herein are the property of Biomet, Inc. or its subsidiaries unless otherwise indicated.

This material is intended for the sole use and benefit of the Biomet sales force and physicians. It is not to be redistributed, duplicated or disclosed without the express written consent of Biomet.

For product information, including indications, contraindications, warnings, precautions and potential adverse effects, see the product labeling.



One Surgeon. One Patient.®

P.O. Box 587, Warsaw, IN 46581-0587 • 800.348.9500 x 1501

©2012 Biomet Orthopedics • biomet.com

Form No. BMET0016.0 • REV053112