

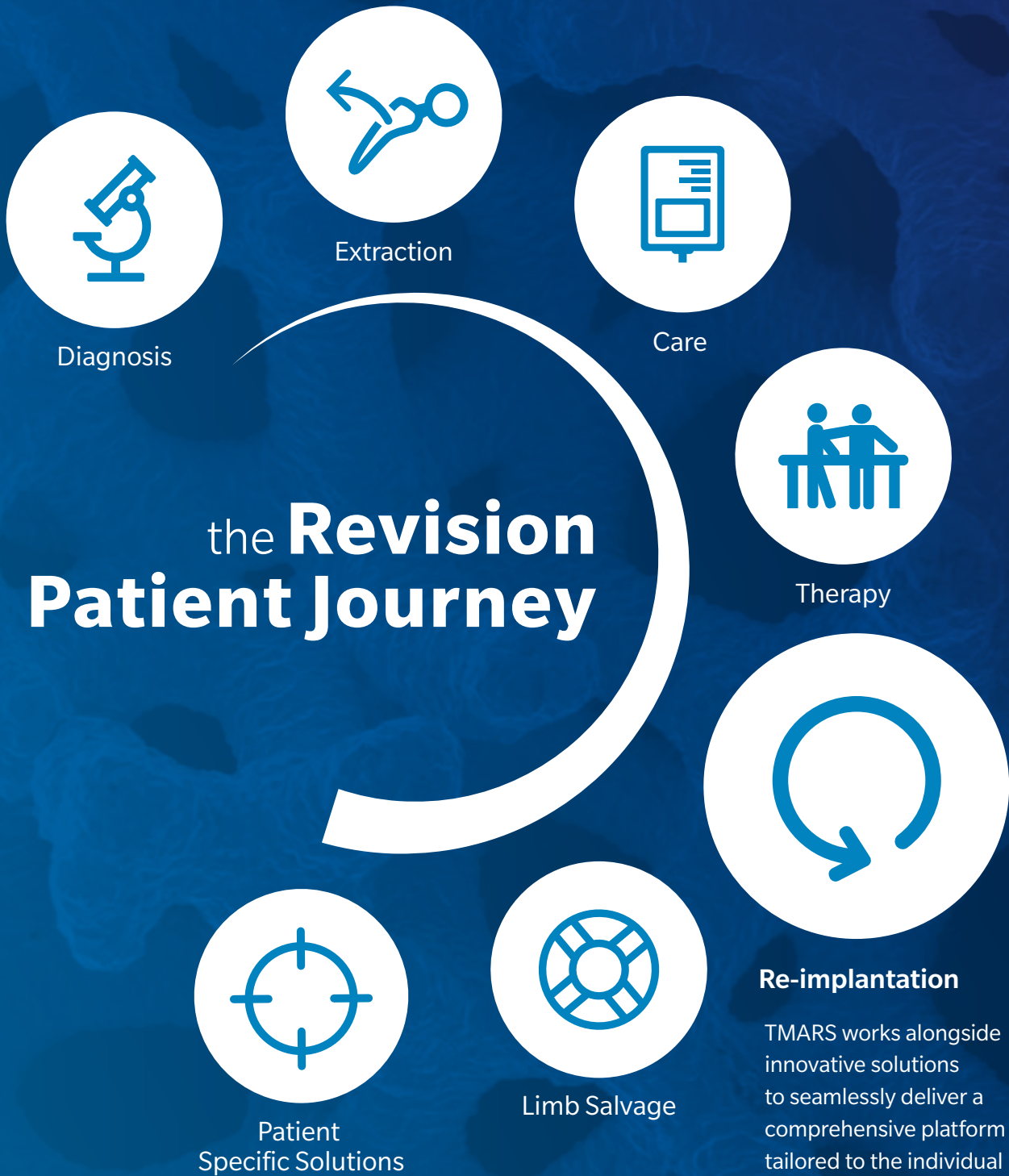Trabecular Metal™ Acetabular Revision System (TMARS)



BREAKING^{the} REVISION CYCLE

Zimmer Biomet offers customers solutions to address the most common issues leading to revision procedures.

It is time to break the revision cycle to focus on the entire patient journey from before, during and after surgery and provide surgeons the tools to make informed decisions in order to establish an appropriate treatment plan. From diagnostics to re-implantation, the innovative solutions seamlessly deliver a comprehensive platform transforming the revision patient journey with customizable, interconnected and interdependent services and solutions.



the **Revision** **Patient Journey**

Diagnosis

Extraction

Care

Therapy

Re-implantation

TMARS works alongside innovative solutions to seamlessly deliver a comprehensive platform tailored to the individual patient needs.

Patient
Specific Solutions

Limb Salvage

Paprosky Acetabular Defect Classification

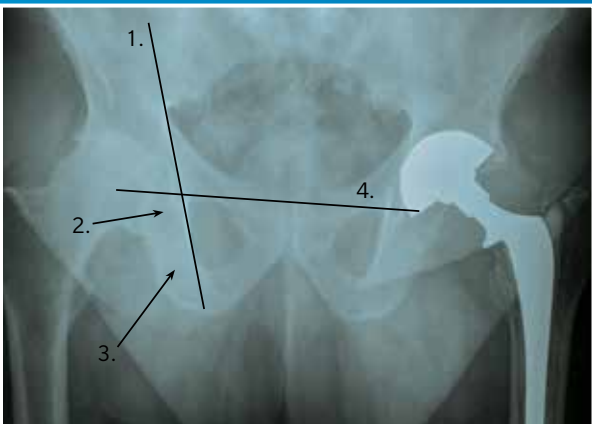
Defects spanning Paprosky Type I through IV have been successfully treated with the TMARS.¹⁻⁶

Initial stability and long-term biologic fixation is key in revision hip arthroplasty. Some revision surgeons may find even more challenges due to severe bone loss in a patient. By leveraging our advanced technologies with an algorithmic approach, an extensive range of patients with Paprosky's Acetabular Defects can be treated and mobility restored.

Four Landmarks

Indications for component revision are dependent upon four **radiographic criteria**.

Radiographic Criteria



1. Kohler's Line:

Integrity of medial wall and superior column

2. Acetabular Tear Drop:

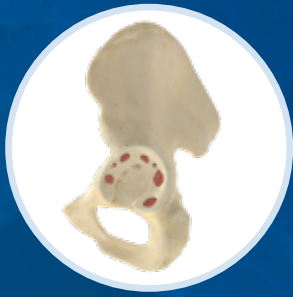Integrity of medial wall and inferior portion of anterior and posterior column

3. Ischial Lysis:

Integrity of posterior wall and posterior column

4. Vertical Migration:

Integrity of superior dome



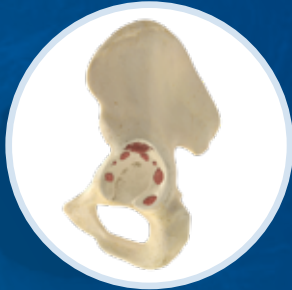Type I & IIA

Type I Defect Characteristics

Acetabular rim, anterior column, and posterior column intact and supportive; small, local, contained defects

Type IIA Defect Characteristics

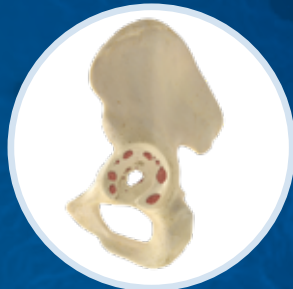Moderate superomedial migration <3 cm; >50% host-bone contact



Type IIB

Type IIB Defect Characteristics

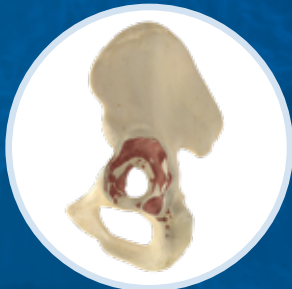
Moderate superolateral migration <3 cm; >50% host-bone contact



Type IIC

Type IIC Defect Characteristics

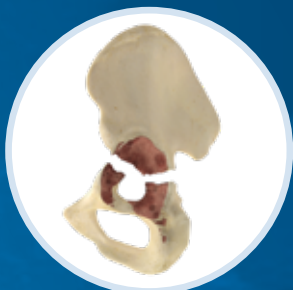Isolated medial migration, medial to Kohler's line; intact rim



Type IIIA

Type IIIA Defect Characteristics

Severe superolateral migration >3 cm; 40–60% host-bone contact; inadequate stability; defect <1/2 circumference



Type IV

Type IV Pelvic Discontinuity Characteristics

Partial or complete fracture

INDIVIDUALIZED SOLUTIONS FOR EVERY PATIENT

TMARS allows surgeons to have flexibility, longevity and reliability within one system that boasts a clinical history of over 20 years.⁷⁻⁹ By combining clinically proven Trabecular Metal Technology⁷⁻⁹ with an array of augments, liners, shells, buttresses and cages, a surgeon can form and customize a construct to better address acetabular defects, poor bone quality and personalize care.

Flexibility

Mix and match implants intraoperatively, enabling more efficient case management and execution.

The Right Fit

Interfaces are cemented against the Trabecular Metal Revision Shell, creating a monolithic construct without concerns of micromotion.





Fixation

Fully-interconnected trabecular structure enables tissue and bony in-growth.¹⁰

Stability

Cemented liners are designed to allow for placement at the exact coverage angle and have a grooved backside to provide rotational stability.

Mitigate Challenges

Secure mechanical and biologic fixation for a stable construct without the the need for graft resorption or structural allograft.¹¹

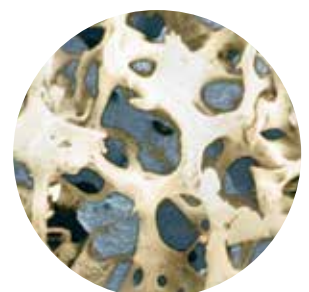
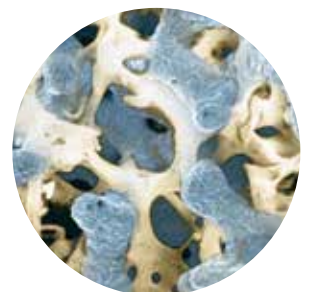
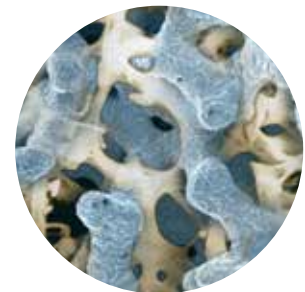


ADVANCED TECHNOLOGY IN ONE SYSTEM

TMARS features modularity as well as a variety of other **technologies** within **one comprehensive system** to provide a **simple solution** to the surgeon in challenging acetabular revisions.

Trabecular Metal

- Evidence supporting Trabecular Metal acetabular components is well-documented across more than **300** publications.
- Trabecular Metal cups used in revision THA have shown to be **21% less** likely to be re-revised due to infection and **11% less** likely to be re-revised for any reason.¹¹⁻¹³
- **Up to 80%** porosity with **100%** open, interconnected pore structure, designed to support bony in-growth and vascularization.¹⁴
- **65% less** likely to be revised for aseptic loosening compared to non-TM cups.¹⁵



Augments, Cages and Shells

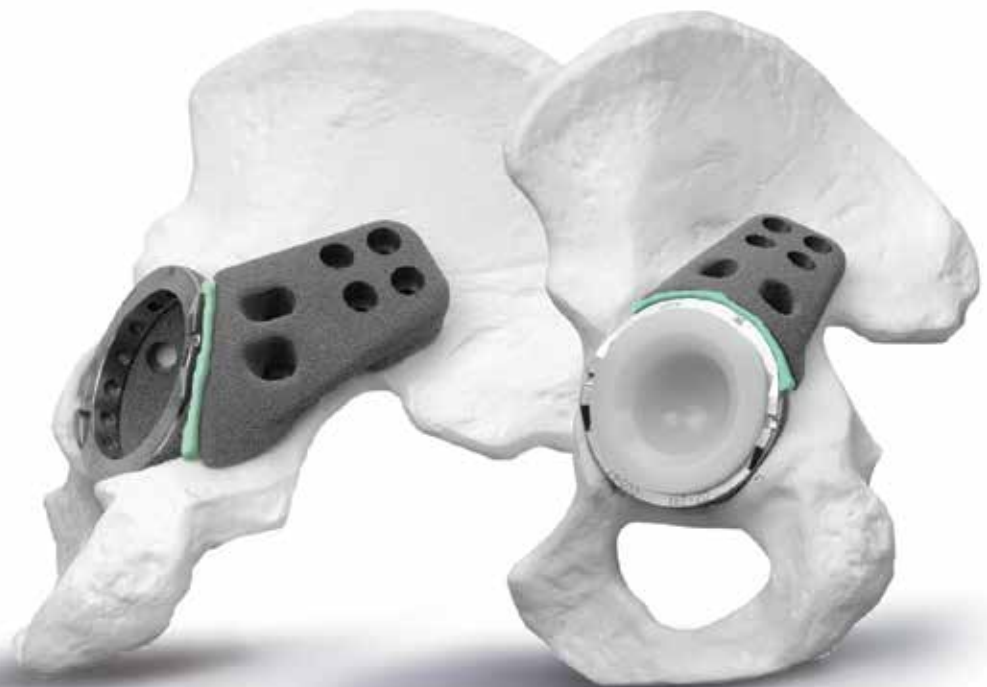- Shims placed between the buttress augment flange and host bone **optimize** the fit of the device against iliac bone conserving host bone and providing **structural support**.
- Cages can be contoured to fit the acetabulum while providing mechanical **stability**.
- Restrictors and augments come in many **sizes** supporting coverage of defects.
- Revision shells **feature** multiple hole options to support the system.



ADVANCED TECHNOLOGY IN ONE SYSTEM

Bone Cement

- For TMARS, bone cement is used to cement the liner to the shell, cage and between any augments to create a monolithic structure.
- High-viscosity bone cement, with and without antibiotics.
- Reliable performance based on international laboratory testing.¹⁶
- Green color for easy recognition during surgery.
- Easy handling with modern vacuum mixing systems standards.¹⁷



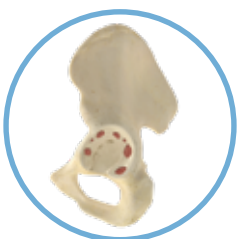Constrained Liners

- Designed for **performance** and **dislocation** resistance.
- Longevity® Highly Cross-linked Polyethylene is used in up to **19%** of revision **THAs**, highly resistant to wear and aging.¹⁸⁻²⁰
- RSA study demonstrates proximal head penetration in Longevity inserts is **significantly lower** than conventional polyethylene.^{19,10}
- Traditional constrained inserts can **restrict** range of motion, potentially leading to implant-on-implant impingement. This could lead to component failure,^{19,20} further dislocation,²¹ or implant loosening.¹⁹

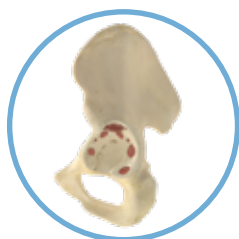

RECONSTRUCTION OPTIONS

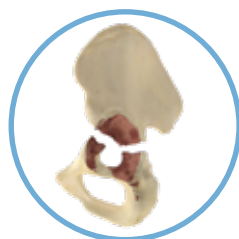We utilize Paprosky's Defect Classification to discuss revision and better develop solutions both intraoperatively and preoperatively. Utilizing the modularity of TMARS while defining reconstruction options based on the radiographic criteria, we can address the severity of bone loss and the ability to obtain cementless fixation all for a given bone-loss pattern. Depending upon your radiographic criteria and your understanding of the defects the patient may exhibit, TMARS can help in planning your approach to reconstruction.



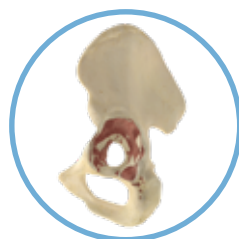
Type I & IIA



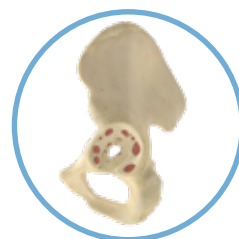Type IIB



Type IV



Type IIIA



Type IIC

The integrity of the host-bone stock determines the reconstruction option available:

Completely supportive acetabulum (ingrowth likely)

- Trabecular Metal Revision Shell

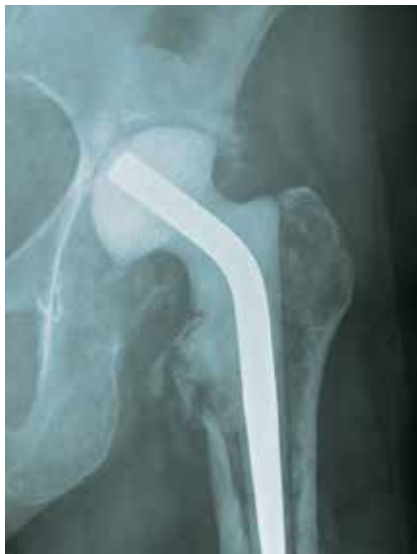Partially supportive acetabulum (ingrowth possible)

- Trabecular Metal Revision Shell with Augments

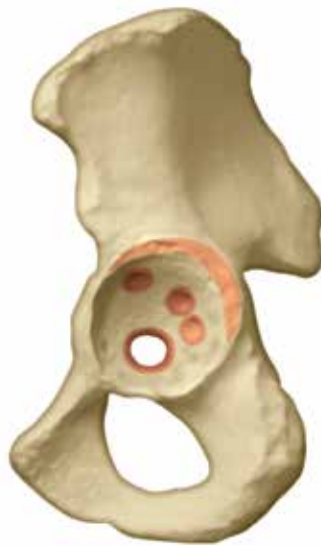Non-supportive (ingrowth unlikely)

- Trabecular Metal Revision Shell with Buttress Augments and/or Cage

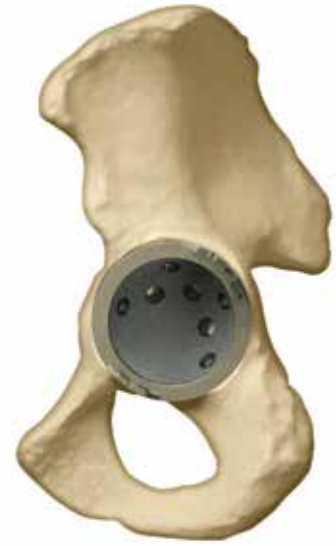Type I & Type II Defects



Radiograph of Defect



Example of Defect



Algorithmic Repair

Type I Defect

Kohler's Line: Intact

Tear Drop: Intact

Ischial Lysis: Minimal to none

Vertical Migration: Minimal to none

Type IIA Defect

Kohler's Line: Intact

Tear Drop: Violated

Ischial Lysis: Mild to moderate

Vertical Migration: Minimal to none

Type IIB Defect

Kohler's Line: Intact

Tear Drop: Intact

Ischial Lysis: Mild

Vertical Migration: <3 cm

Type IIC Defect

Kohler's Line: Moderately violated

Tear Drop: Moderate lysis

Ischial Lysis: Minimal

Vertical Migration: Minimal to none

Solution

Trabecular Metal Revision Shell and Longevity® Highly Crosslinked Polyethylene Liner

- Designed to prevent backside micromotion

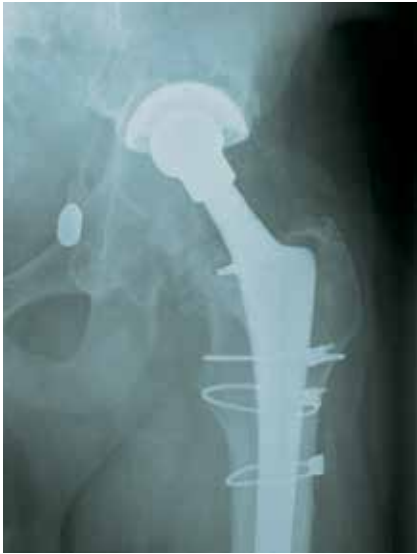- Cement secures screws

- Isoelastic loading of bone

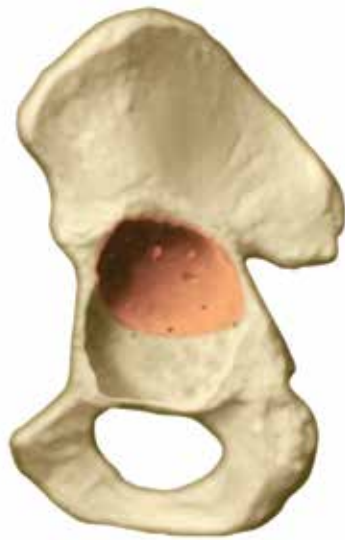- Cemented Longevity Highly Crosslinked Polyethylene Liners with large-diameter heads, up to 40 mm, for additional joint stability and range of motion



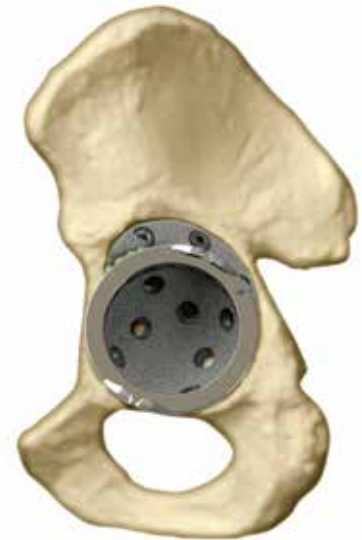Type IIIA—Cavitary Defect



Radiograph of Defect



Example of Defect



Algorithmic Repair

Type IIIA Cavitary Defect

Kohler's Line: Intact

Tear Drop: Minimal lysis

Ischial Lysis: Minimal

Vertical Migration: >3 cm

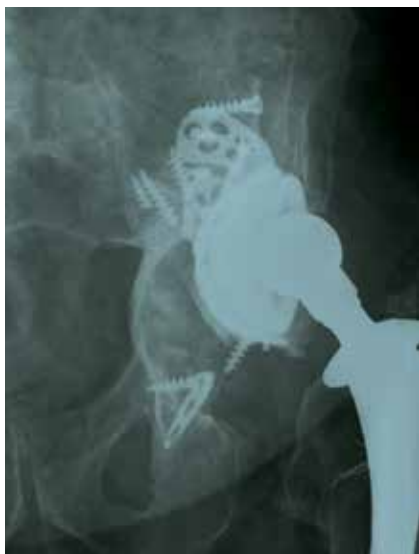Solution

Trabecular Metal Augment in oblong cup position^{2,16-18}

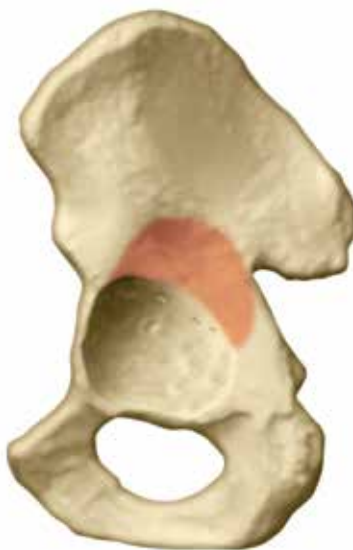- Uses the Trabecular Metal Augment to fill the superior bone void and restore head center to natural anatomic position
- Cementing the Trabecular Metal Revision Shell to the augment creates a monolithic construct



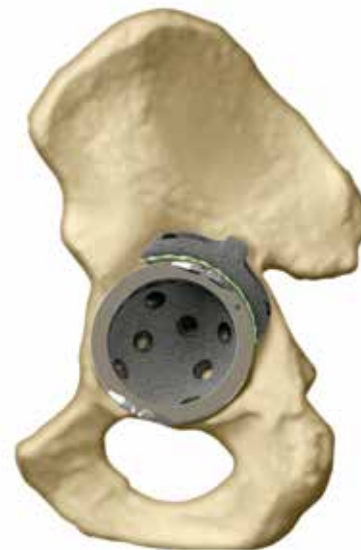Type IIIA—Segmental Defect



Radiograph of Defect



Example of Defect



Algorithmic Repair

Type IIIA Segmental Defect

Kohler's Line: Moderately violated but intact

Tear Drop: Minimal lysis

Ischial Lysis: Mild

Vertical Migration: >3 cm

Solution

Trabecular Metal Augment in flying buttress position^{1-2,8-10}

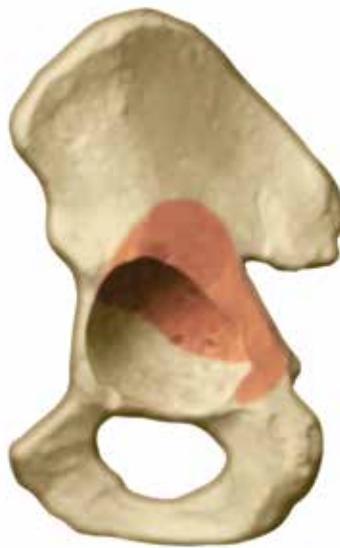- Uses the Trabecular Metal Augment, inverted, as a load-bearing structural support to replace the missing acetabular rim
- Cementing the Trabecular Metal Revision Shell to the augment creates a monolithic construct



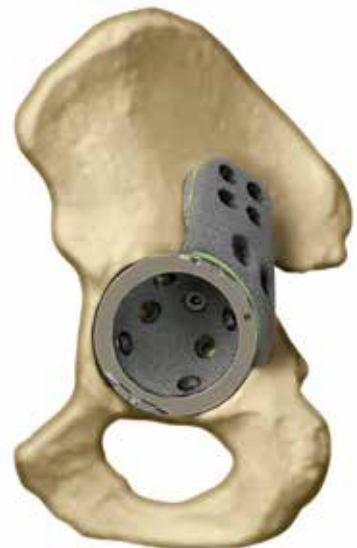Type IIIA—Extensive Segmental Defect



Radiograph of Defect



Example of Defect



Algorithmic Repair

Type IIIA Extensive Segmental Defect

Kohler's Line: Intact

Tear Drop: Minimal lysis

Ischial Lysis: Mild

Vertical Migration: >3cm

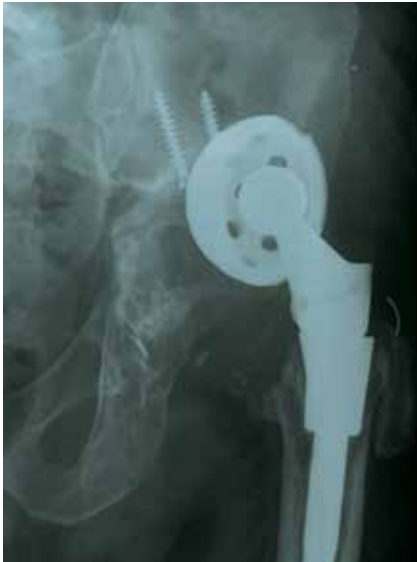Solution

Trabecular Metal Buttress Augment

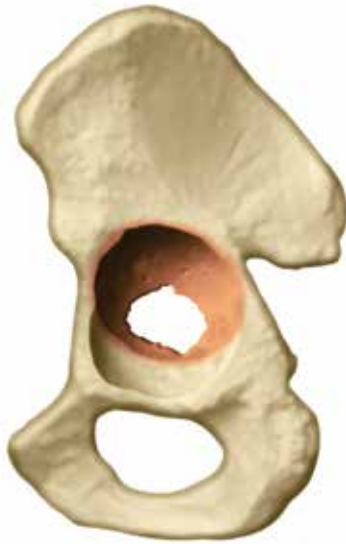- Trabecular Metal Buttress Augment provides a superior step for placement against the ilium and is an alternative to allografts.
- Trabecular Metal Shim Augments are available to supplement the fit of the superior flange of the buttresses onto the ilium
- Cementing the Trabecular Metal Revision Shell to the augment creates a monolithic construct



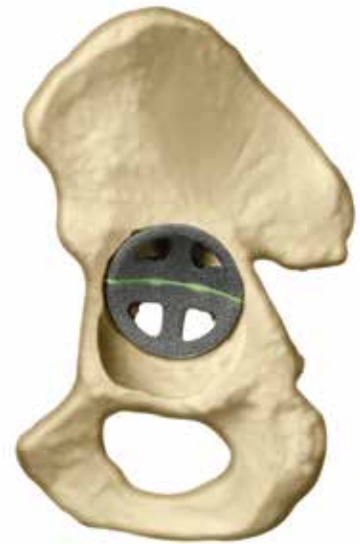Type IIIB—Contained Medial Defect



Radiograph of Defect



Example of Defect



Algorithmic Repair Step 1

Type IIIB Medial Defect

Kohler's Line: Violated

Tear Drop: Violated, significant lysis

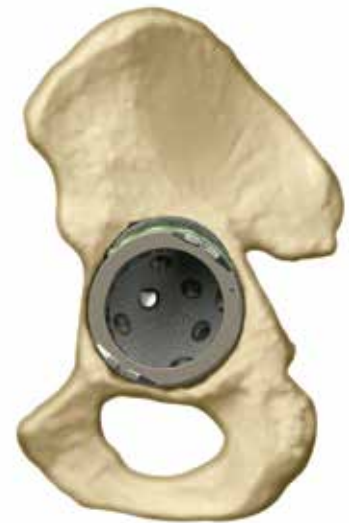Ischial Lysis: Severe

Vertical Migration: >3 cm

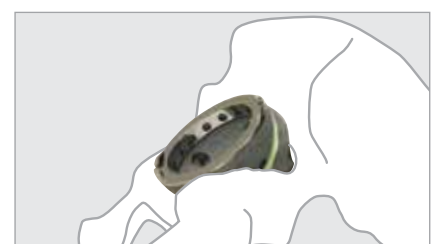Solution

Trabecular Metal Augments in footings position^{1-6,8}

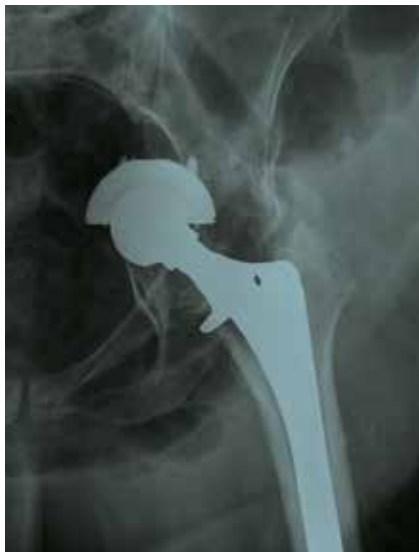- Trabecular Metal Augments sized to fit defect, providing a foundation for the shell and filling voids from medial and/or superior defects
- Cementing the Trabecular Metal Revision Shell to the augments creates a monolithic construct



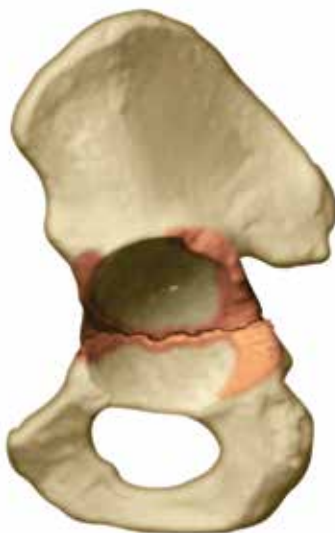Algorithmic Repair Step 2



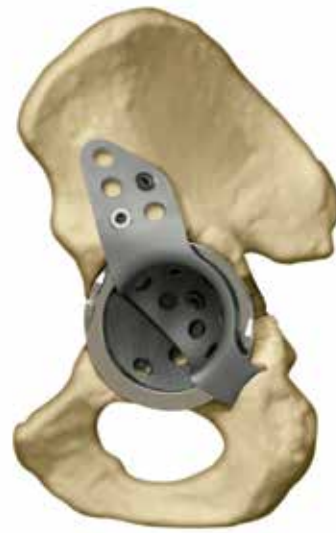Pelvic Discontinuity



Radiograph of Defect



Example of Defect



Algorithmic Repair

Pelvic Discontinuity

- Superior aspect of pelvis is separated from the inferior aspect as a result of bone loss or an acetabular fracture.
- If the defect is extensive and adequate stability cannot be reached through TMARS, it may require a custom device specifically matched to the patient's unique anatomy. Zimmer Biomet's Triflange Acetabular component is a patient-matched implant designed in partnership with the surgeon, using the patient's own CT scan data and could be considered as an option in this case.



Solution

Cup-Cage Construct

- The Cage spans the acetabular defect and provides mechanical stability until biological ingrowth occurs within the Trabecular Metal Revision Shell
- Used in situations where the Trabecular Metal Revision Shell alone does not provide adequate stability
- The Trabecular Metal Revision Shell provides potential for bone ingrowth and long-term fixation
- Three components—shell, cage, and liner—cemented together create a monolithic construct



References

1. Paprosky, W., *et al.* Acetabular Defect Classification and Surgical Reconstruction in Revision Arthroplasty: A 6-year Follow-up Evaluation. *J Arthroplasty*. 9: 33–44, 1994.
2. Lewallen, D.G., *et al.* Revision Hip Arthroplasty with Porous Tantalum Augments and Acetabular Shells. Scientific Exhibition: 73rd Annual Meeting of the American Academy of Orthopaedic Surgeons. Chicago, IL. 2006.
3. Macheras, G.A., *et al.* Eight to Ten-Year Clinical and Radiographic Outcome of a Porous Tantalum Monoblock Acetabular Component. *JOA In Press*. 00: (02008).
4. Weeden, S.H., *et al.* The Use of Tantalum Porous Metal Implants for Paprosky Type 3A and 3B Implants. *J Arthroplasty*. 22(6) (suppl 2): 151–155. 2007.
5. Sporer, S., *et al.* Acetabular Revision Using a Trabecular Metal Acetabular Component for Severe Acetabular Bone Loss Associated with a Pelvic Discontinuity. *J Arthroplasty*. 21(6): 2006.
6. Lachiewicz, P., *et al.* Tantalum Components in Difficult Acetabular Revisions. *Clin Orthop Relat Res*. 468: 454–458, 2010.
7. Lakstein, D., *et al.* A Trabecular Metal Cups for Acetabular Defects for 50% or Less Host Bone Contact. *Clin Orthop Relat Res*. 467(9): 2318–2324, 2009.
8. Nakashima, Y., *et al.* Clinical and Radiographic Evaluation of Total Hip Arthroplasties Using Porous Tantalum Modular Acetabular Components: 5-Year Follow-up of Clinical Trial. *Modern Rheumatology*. 23(1): 112–118, 2013.
9. Simon, J.P., *et al.* Clinical and Radiological Evaluation of Modular Trabecular Metal Acetabular Cups- Short-Term Results in 64 Hips. *Acta Orthop Belg*. 75: 623–630, 2009.
10. Bobyn, J.D., *et al.* Characterization of a New Porous Tantalum Biomaterial for Reconstructive Orthopaedics. *Scientific Proc of AAOS*. Anaheim, CA. 1999.
11. Nehme, A. *et al.* Modular Porous Metal Augments for Treatment of Severe Acetabular Bone Loss During Revision Hip Arthroplasty. *Clinical Orthopaedics and Related Research*. 429: 201, 2004.
12. According to NJR data from 2003 to 2015 where 9,573 Trabecular Metal and 30,452 non-Trabecular Metal cups were used in revision THA and based on hazard ratios adjusted by patient gender, age group, and indications (OA/non-OA). The complete NJR report can be found at zimmerbiomet.com/TM.
13. NJR data shows a higher percentage of TM cups were used with antibiotic bone cement compared to all other non-TM cementless cups. The complete NJR report can be found at zimmerbiomet.com/TM.
14. Karageorgious, V. *et al.*, Porosity of 3D Biomaterial Scaffolds and Osteogenesis. *Biomaterials*, 27 (27): 5474–91, Sep. 2005.
15. Matharu, GS. *et al.* Trabecular metal acetabular components reduce the risk of revision following primary total hip arthroplasty: A propensity score matched study from the National Joint Registry for England and Wales. *The Journal of Arthroplasty*. 33(2): 447–52, 2018.
16. Data on file at Zimmer Biomet, internal laboratory testing results, 2016. Laboratory testing is not necessarily indicative of clinical performance
17. ISO 5833, Implants for Surgery - Acrylic Resin Cements (2002).
18. Kaper BP, Bernini PM. Failure of a constrained acetabular prosthesis of a total hip arthroplasty – a report of four cases. *J Bone Joint Surg, Am*. 1998; Apr;80(4):561–5
19. Digas G, *et al.* Highly crosslinked polyethylene in total hip arthroplasty: randomized evaluation of penetration rate in cemented and uncemented sockets using radiostereometric analysis. *Clin Orthop & Rel Res*. 2004;429:6;46–52
20. Fisher DA, Kiley K. Constrained acetabular cup disassembly. *J Arthroplasty*. 1994; Jun;9(3):325–9
21. Anderson MJ, Murray WR, Skinner HB. Constrained acetabular components. *J Arthroplasty*. 1994; Feb;9(1):17–2

All content herein is protected by copyright, trademarks and other intellectual property rights, as applicable, owned by or licensed to Zimmer Biomet or its affiliates unless otherwise indicated, and must not be redistributed, duplicated or disclosed, in whole or in part, without the express written consent of Zimmer Biomet.

This material is intended for health care professionals. Distribution to any other recipient is prohibited.

For indications, contraindications, warnings, precautions, potential adverse effects and patient counseling information, see the package insert or contact your local representative; visit www.zimmerbiomet.com for additional product information.

Not for distribution in France. Check for country product clearances and reference product specific instructions for use.

For training and educational events, join our network at zbinetwork.com.

©2019 Zimmer Biomet



 **Legal Manufacturer**
Zimmer, Inc.
1800 W. Center Street
Warsaw, IN 46580
USA

Zimmer Trabecular Metal
Technology, Inc.
10 Pomeroy Road
Parsippany, New Jersey 07054
USA

www.zimmerbiomet.com

2092.2-GLBL-en-REV0619