

AmnioRepair[®]

Diabetic Foot Ulcer Case Studies

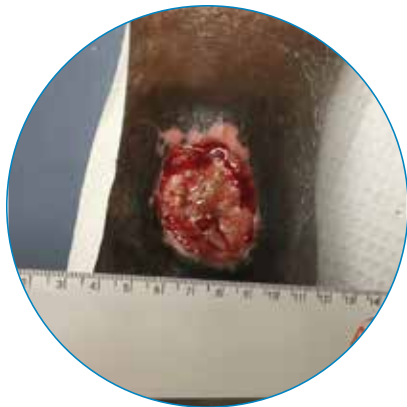

Lyophilized Placental
Membrane

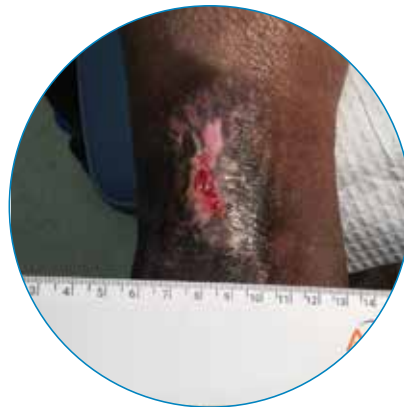Case 1

A 50-year-old male patient presented with a 14.0 cm² diabetic foot ulcer on his anterior right ankle. He was a non-smoker with a BMI of 31.6. The wound was greater than 30 days old and a Grade 2 on the Wagner Scale, extending into bone.

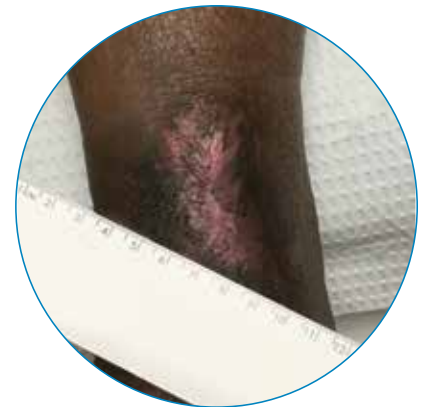Treatment: An offloading device was used, and debridement was performed prior to each AmnioRepair® application. Complete wound closure with no drainage and complete re-epithelialization was achieved in 84 days after a total of 9 weekly AmnioRepair applications.



Day 0



Day 63

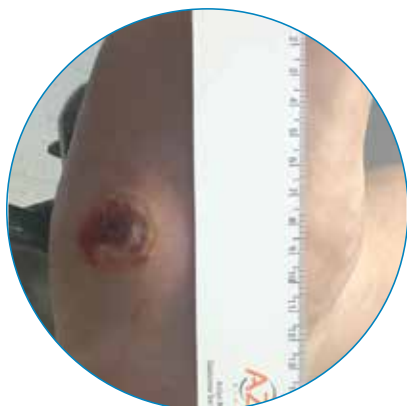


Day 84

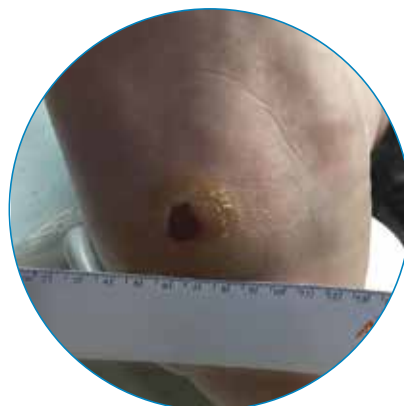Case 2

A 49-year-old male patient presented with a 9.0 cm² diabetic foot ulcer on the plantar side of his right foot. This diabetic patient had an A1C of 7.8, had never smoked and had a BMI of 44.8. The wound was greater than 90 days old and a Grade 2 on the Wagner Scale.

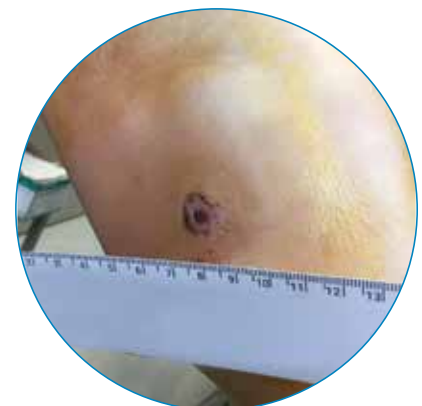Treatment: An offloading device was used, and debridement was performed prior to each AmnioRepair application. Complete wound closure with no drainage and complete re-epithelialization was achieved in 71 days following a total of 10 weekly AmnioRepair applications.



Day 0



Day 43

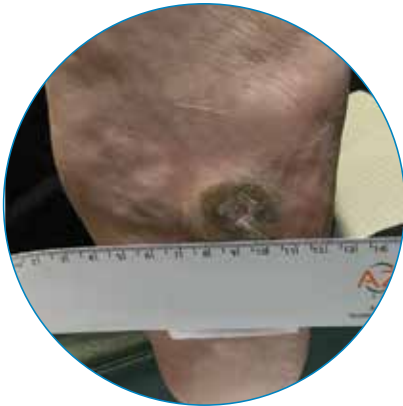


Day 71

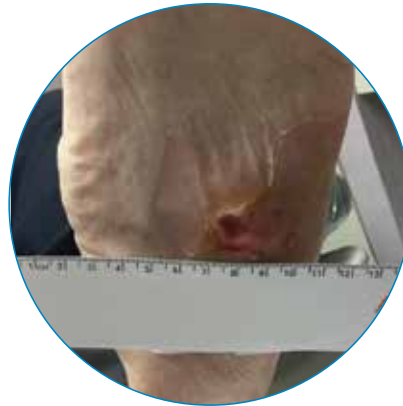
Case 3

A 76-year-old male patient presented with 4.1 cm² diabetic foot ulcer on the plantar side of his left foot. This diabetic patient had an A1C of 6.7, was a non-smoker and had a BMI of 32.3. The wound was present for greater than 30 days and was a Grade 2 on the Wagner Scale. The patient's wound had previously failed to close after 10 applications of another advanced therapy.

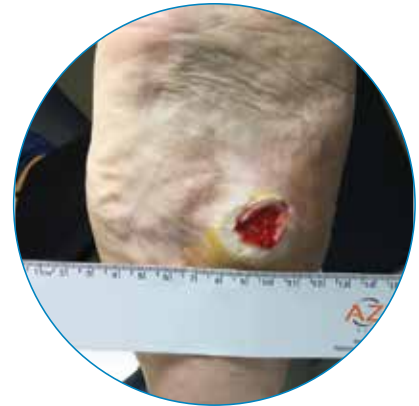Treatment: An offloading device was used, and debridement was performed weekly prior to each AmnioRepair application. Complete wound closure with no drainage and complete re-epithelialization was achieved in 83 days following a total of 9 weekly AmnioRepair applications.



Day 0



Day 42

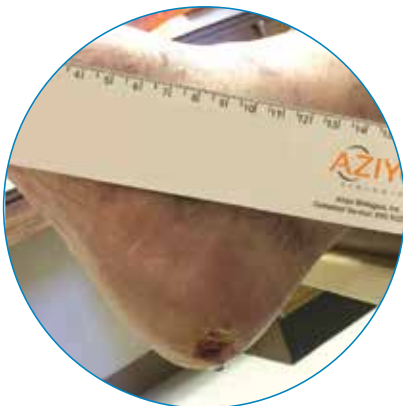

Day 83


Case 4

A 76-year old female patient presented with a 1.2 cm² diabetic foot ulcer on the plantar side of her right heel. She was a non-smoker and had a BMI of 22.3. Her wound was present for greater than 90 days and was a Grade 2 on the Wagner Scale.

Treatment: An offloading device was used, and debridement was performed prior to each AmnioRepair application. Complete wound closure with no drainage and complete re-epithelialization was achieved in 21 days after 2 AmnioRepair applications.



Day 0



Day 21

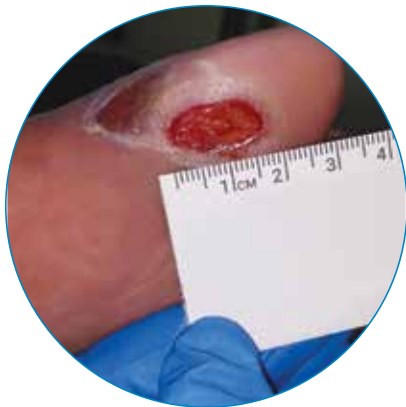

Day 28

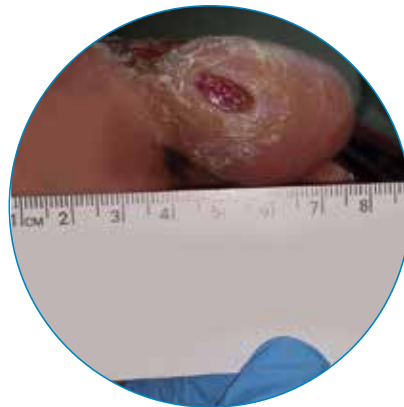
Case 5

A 71-year-old male patient presented with a 1.7 cm² diabetic foot ulcer on the plantar side of his left phalange. This diabetic patient had an A1C of 6.1, was a former smoker and had a BMI of 38.0. The wound was present for approximately 30 days and was a Grade 1 on the Wagner Scale.

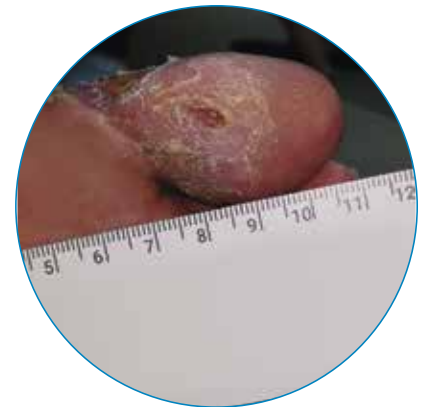
Treatment: Debridement was performed prior to each AmnioRepair application. Complete wound closure with no drainage and complete re-epithelialization was achieved in 21 days following 3 weekly AmnioRepair applications.



Day 0



Day 16

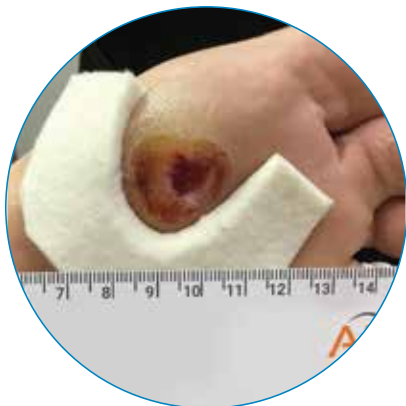

Day 21

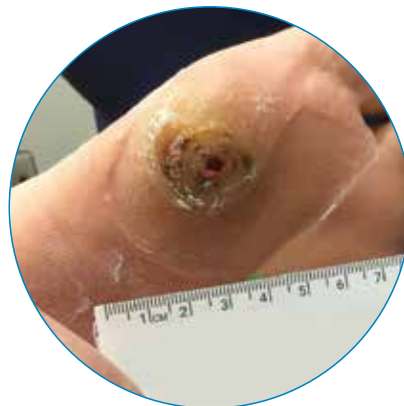Case 6

A 55-year-old male patient presented with a 1.5 cm² diabetic foot ulcer on the plantar side of his left metatarsal. This diabetic patient had an A1C of 9.0, had never smoked and had a BMI of 34.0. The wound was present for approximately 30 days and was a Grade 1 on the Wagner Scale.

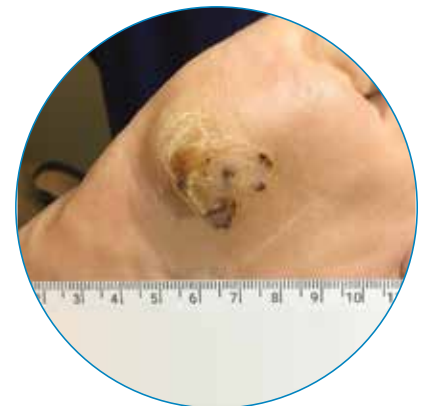Treatment: An offloading device was used, and debridement was performed prior to each AmnioRepair application. Complete wound closure with no drainage and complete re-epithelialization was achieved in 27 days following 3 weekly AmnioRepair applications.



Day 0



Day 13

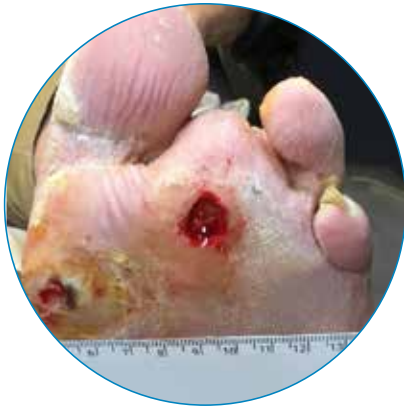

Day 27

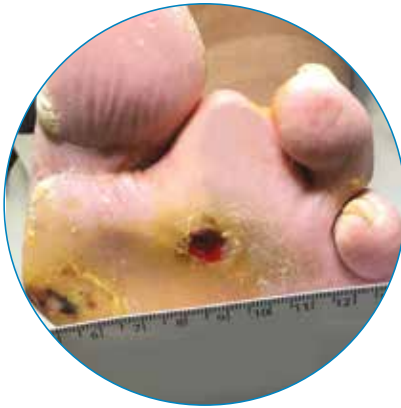
Case 7

An 86-year-old male patient presented with a 1.5 cm² diabetic foot ulcer on the plantar side of his left metatarsal. This diabetic patient was a former smoker and had a BMI of 28.0. The wound was present for greater than 90 days and was a Grade 2 on the Wagner Scale. The patient had previously failed 10 applications of another advanced therapy.

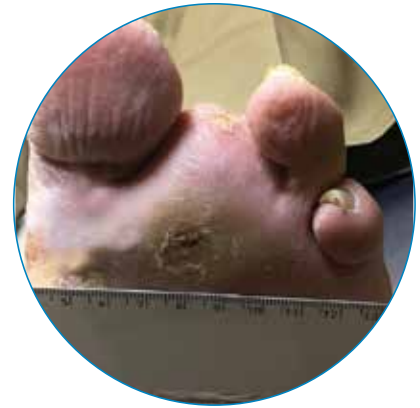Treatment: An offloading device was used, and debridement was performed prior to each AmnioRepair application. Complete wound closure with no drainage and complete re-epithelialization was achieved in 35 days following 4 weekly AmnioRepair applications.



Day 0



Day 14

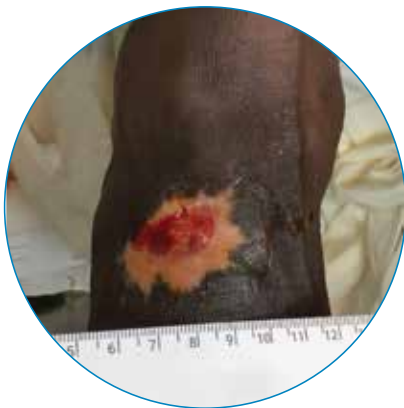

Day 35

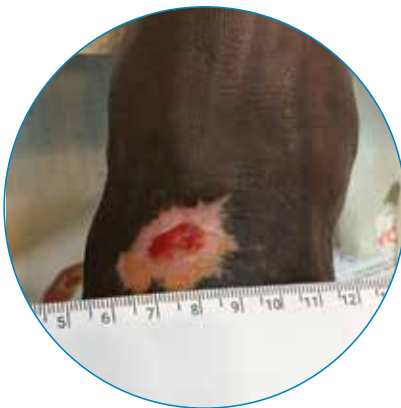Case 8

A 52-year-old male patient presented with a 2.3 cm² diabetic foot ulcer on the dorsal side of his left midfoot. This diabetic patient was a smoker at the time of treatment and had a BMI of 21.6. The wound was present for greater than 30 days and was a Grade 2 on the Wagner Scale.

Treatment: An offloading device was used, and debridement was performed prior to each AmnioRepair application. Complete wound closure with no drainage and complete re-epithelialization was achieved in 49 days following 3 weekly AmnioRepair applications.



Day 0



Day 14



Day 49

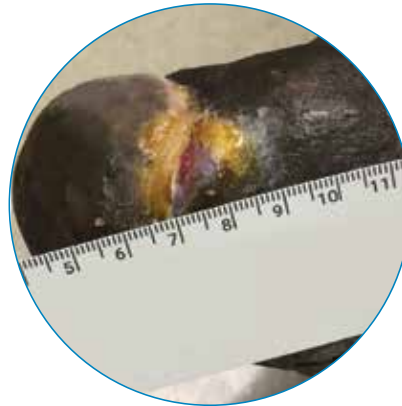
Case 9

A 68-year-old male patient presented with a 2.2 cm² diabetic foot ulcer on the anterior side of his right foot. This diabetic patient was a smoker at the time of treatment and had a BMI of 28.9. The wound was nearly one year old and was a Grade 2 on the Wagner Scale. The patient's wound had previously failed to close after ten applications of another advanced therapy.

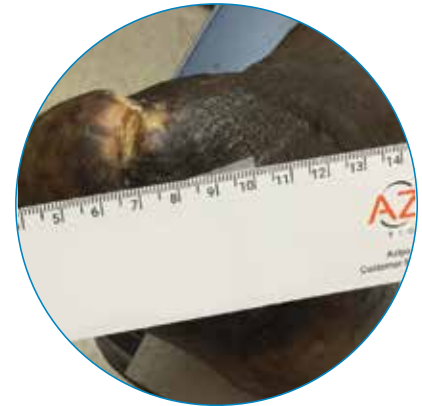Treatment: An offloading device was used, and debridement was performed prior to each AmnioRepair application. Complete wound closure with no drainage and complete re-epithelialization was achieved in 42 days following 6 weekly AmnioRepair applications.



Day 0



Day 21

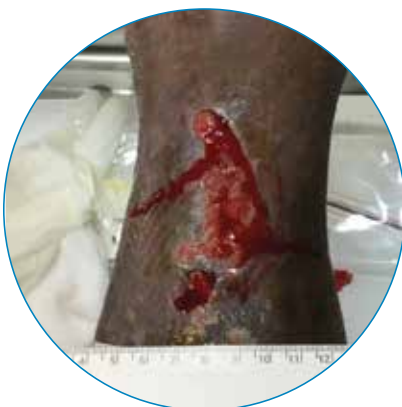

Day 42

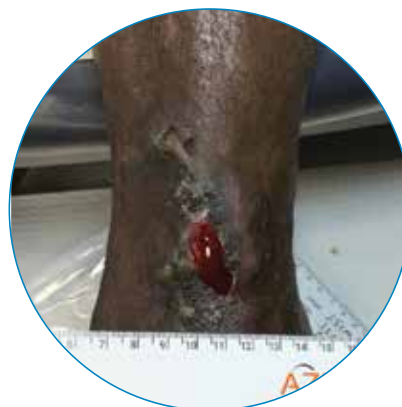Case 10

A 52-year-old male patient presented with a 13.8 cm² diabetic foot ulcer on the dorsal side of his left talus. This diabetic patient had an A1C of 5.8, had never smoked and had a BMI of 38.0. The wound was greater than 90 days old and was a Grade 2 on the Wagner Scale. The patient had previously failed treatment with an advanced therapy.

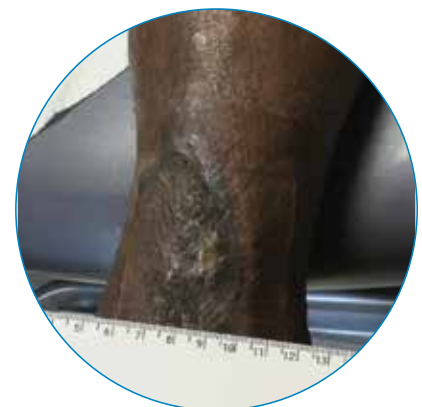Treatment: An offloading device was used, and debridement was performed prior to each AmnioRepair application. Complete wound closure with no drainage and complete re-epithelialization was achieved in 29 days following 3 weekly applications of AmnioRepair.



Day 0



Day 15

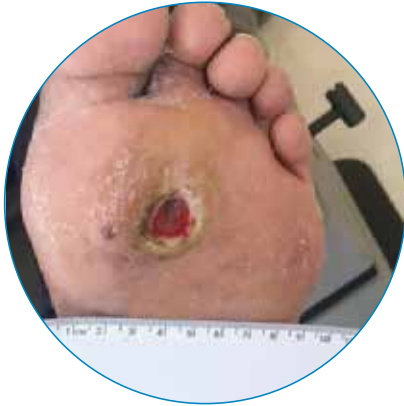

Day 29

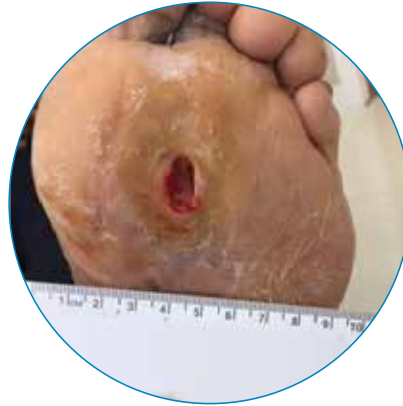Case 11

A 48-year-old male patient presented with a 1.5 cm² diabetic foot ulcer on the plantar side of his left foot. This diabetic patient had never smoked and had a BMI of 29.7. The wound was approximately 30 days old and was a Grade 1 on the Wagner Scale.

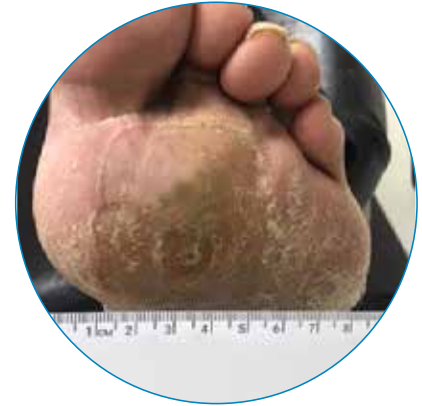Treatment: An offloading device was used, and debridement was performed as needed, prior to most AmnioRepair applications. Complete wound closure with no drainage and complete re-epithelialization was achieved in 79 days following 9 applications of AmnioRepair.



Day 0



Day 28

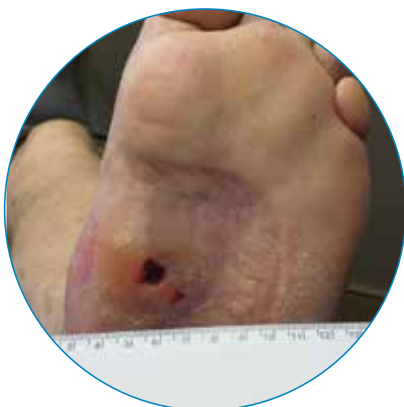

Day 79

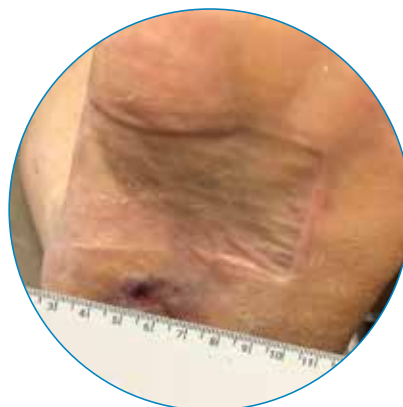Case 12

A 75-year-old male patient presented with a 0.5 cm² diabetic foot ulcer on the plantar side of his left midfoot. This diabetic had never smoked and had a BMI of 31.9. The wound was greater than 90 days old and was a Grade 1 on the Wagner Scale.

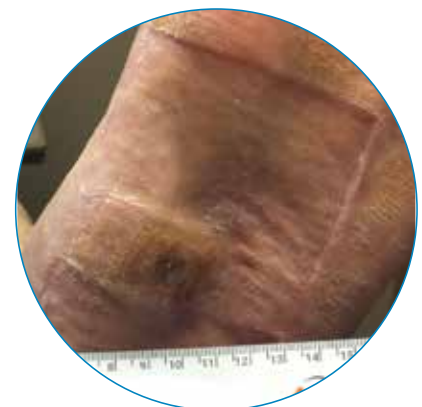
Treatment: An offloading device was used, and debridement was performed prior to each AmnioRepair application. Complete wound closure with no drainage and complete re-epithelialization was achieved in 28 days after 4 weekly applications of AmnioRepair.



Day 0



Day 21



Day 28

Product Description and Indications

AmnioRepair is a lyophilized placental membrane that is aseptically processed to preserve the native extracellular matrix and endogenous proteins of the tissue. AmnioRepair is intended for homologous use as a barrier, forming a protective cover for a variety of acute and chronic wounds. AmnioRepair is sealed in a sterile inner and secondary outer pouch. The outer pouch is contained in a labeled box. Allograft size is indicated on the package label. AmnioRepair is a Human Cellular and Tissue Based Product (HCT/P) per 21 CFR Part 1271. Each allograft is restricted to homologous use for use in procedures on a single occasion by a licensed physician or surgeon.

Storage and Handling

AmnioRepair is supplied ready-to-use and must be stored in its original packaging between at 1°C to 36°C (33.8°F to 96.8°F) until ready for use. It is the responsibility of the transplant facility or clinician to maintain the allograft intended for transplantation in the appropriate recommended storage conditions prior to transplant.

Precautions

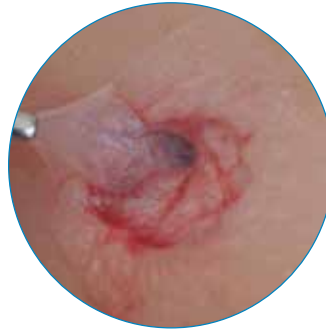Inspect the integrity of the package upon receipt and before use. Do not use AmnioRepair under the following conditions:

- The pouch in which the allograft is stored is damaged or the label has been damaged or defaced.
- The allograft expiration date has passed.
- Recommended storage conditions have not been maintained.

This material is intended for healthcare professionals and the Zimmer Biomet sales force. Distribution to any other recipient is prohibited. For indications, contraindications, warnings, precautions, potential adverse effects and patient counseling information, see the package insert or contact your local representative; visit www.zimmerbiomet.com for additional product information.

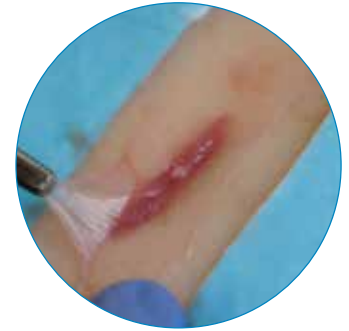All content herein is protected by copyright, trademarks and other intellectual property rights, as applicable, owned by or licensed to Zimmer Biomet or its affiliates unless otherwise indicated, and must not be redistributed, duplicated or disclosed, in whole or in part, without the express written consent of Zimmer Biomet.

Check for country product clearances and reference product specific instructions for use. Zimmer Biomet does not practice medicine.



Chronic Non-healing Wounds

Supports closure of chronic diabetic foot ulcers, venous leg ulcers and pressure wounds.



Surgical Wounds

Enables rapid, nonpathologic healing and remodeling of surgical and reconstructive wounds.

AmnioRepair Ordering Information

Size	Part Number
16 mm DISC	00561800416
2 x 2 cm	00561800422
2 x 3 cm	00561800423
2 x 4 cm	00561800424
3 x 3 cm	00561800433
4 x 4 cm	00561800444
4 x 6 cm	00561800446

This document is intended for surgeons and is not intended for laypersons. Each surgeon should exercise his or her own independent judgment in the diagnosis and treatment of an individual patient, and this information does not purport to replace the comprehensive training surgeons have received. The technique used in each case will depend on the surgeon's medical judgment as the best treatment for each patient. Results will vary based on health, weight, activity and other variables. Not all patients are candidates for this product and/or procedure.

Caution: Federal (USA) law restricts this device to sale by or on the order of a surgeon. Rx only.

©2023 Zimmer Biomet



Legal Manufacturer

Aziyo Biologics, Inc.
880 Harbour Way S, Suite 100
Richmond, CA 94804
Phone: 800-922-3100

www.zimmerbiomet.com

Distributor

Zimmer Biomet
1800 W. Center St.
Warsaw, IN 46580