

Core Decompression in Avascular Necrosis

By Jason Le Cocq, M.D.

Introduction

Avascular necrosis (AVN) of the femoral head is a disease commonly associated with corticosteroid use, alcohol abuse, trauma and sickle cell disease. In the United States, between 10,000 and 20,000 people are affected by this pathology annually, aged mostly in their late 30s to early 40s (Figure 1).¹ Likewise, although no definitive figures have been collected globally, extrapolation calculations estimate incidence within the European region of nearly 20,000 patients, 40,000 patients in India and nearly 5,000 patients in Japan.² The young to middle-aged patient population necessitates a joint saving procedure that prevents or postpones an undesirable total joint arthroplasty.³⁻⁵ This is especially critical for patients with sickle cell disease, as 90% of those with AVN experience femoral head collapse within two years of diagnosis and also tend to have higher failure rates and more complications with arthroplasty.⁶

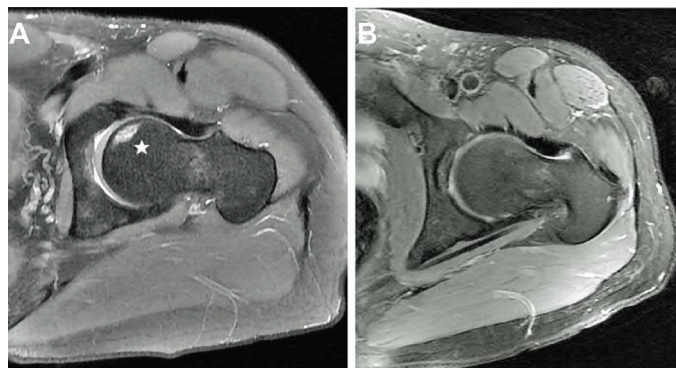


Figure 1 (Image reprinted with permission, Dove Medical Press LTD.)

Treatment

Increased awareness has led to a two-fold increase in the number of AVN-related surgical procedures from 1992 thru 2008 as well as a better understanding of post-treatment prognoses.⁷ For example, several studies, including a recently released large, retrospective analysis, displayed a direct correlation between later diagnosis and treatment relating to the eventual progression to collapse of the joint.⁷⁻¹² These results underscore the importance in early diagnosis and treatment of AVN. Likewise, an increased size of the femoral head lesion (>30%) radiographically, increases the risk of disease progression and complicates joint-preserving treatments.^{11,13-15}

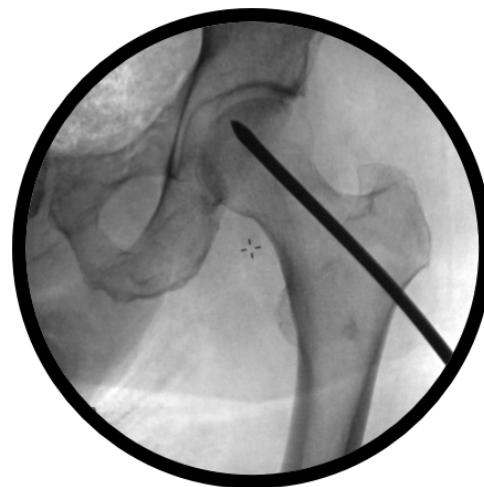

Figure 2

Accordingly, treatment options for AVN have evolved over time. Core decompression (CD) has for several decades been a standard of care in attempting to reduce the pain and pressure caused by an osteonecrotic lesion.¹⁶ CD is a surgical procedure whereby an instrument is inserted, often under radiographic guidance, through the trabecular bone and into a given necrotic space (Figure 2). According to the American Association of Hip and Knee Surgeons (AAHKS), CD is the most common treatment chosen for an osteonecrotic femoral head in a pre-collapse stage.¹⁷ In numerous clinical trials, when used for smaller lesions, CD results have shown promise.^{9,18-24}

Conclusion

CD is a widely practiced, standard joint preserving treatment option in patients with early stage osteonecrosis.^{16,25} While numerous studies^{12,14,16,20,22,23} recommend several weeks of post-operative non-weight bearing, Martin, *et al*, demonstrated an immediate return to weight bearing as tolerated with crutches, post-operatively.²⁶ Use of a small-diameter instrument allows for reduced weakening and injury to the existing structure.⁹ Numerous etiologies have a predisposition for AVN including steroids, alcoholism and sickle cell disease. Lastly, CD greatly increases the potential for cost-effectiveness if it delays THA for 5 or more years.²⁵

Jason Le Cocq, M.D.
Biomet, Office of Medical Affairs
(574) 371-3898
jason.lecocq@biomet.com

References

1. Lavernia CJ, Sierra RJ, Grieco FR. Osteonecrosis of the femoral head. *Journal of the American Academy of Orthopaedic Surgeons* 1999; 7(4):250-261.
2. CureResearch.com. Statistics by country for Avascular Necrosis. 2010. Health Grades, Inc. 5-19-2014.
3. Drescher W, Pufe T, Smeets R, Eisenhart-Rothe RV, Juger M, Tingart M. [Avascular necrosis of the hip-diagnosis and treatment]. *Zeitschrift für Orthopädie und Unfallchirurgie* 2011; 149(2):231-240.
4. Ibrahim V, Dowling H. Platelet-rich plasma as a nonsurgical treatment option for osteonecrosis. *PMR* 2012; 4(12):1015-1019.
5. Kaushik AP, Das A, Cui Q. Osteonecrosis of the femoral head: An update in year 2012. *World Journal of Orthopedics* 2012; 3(5):49.
6. Neumayr LD, Aguilar C, Earles AN *et al.* Physical therapy alone compared with core decompression and physical therapy for femoral head osteonecrosis in sickle cell disease. Results of a multicenter study at a mean of three years after treatment. *The Journal of Bone & Joint Surgery Am* 2006; 88(12):2573-2582.
7. Johnson AJ, Mont MA, Tsao AK, Jones LC. Treatment of femoral head osteonecrosis in the United States: 16-year analysis of the nationwide inpatient sample. *Clinical Orthopaedics and Related Research* 2014; 472(2):617-623.
8. Fernandes M. Therapeutic Autologous Concentrated Bone-Marrow Grafting for the Repair of Early Femoral Osteonecrosis. 2013.
9. Marker DR, Seyler TM, Ulrich SD, Srivastava S, Mont MA. Do modern techniques improve core decompression outcomes for hip osteonecrosis? *Clinical Orthopaedics and Related Research* 2008; 466(5):1093-1103.
10. Steinberg ME, Larcom PG, Strafford B *et al.* Core decompression with bone grafting for osteonecrosis of the femoral head. *Clinical Orthopaedics and Related Research* 2001; 386(7):71-78.
11. Yan Z, Hang D, Guo C, Chen Z. Fate of mesenchymal stem cells transplanted to osteonecrosis of femoral head. *J Orthop Res* 2009; 27(4):442-446.
12. Yoshioka T, Mishima H, Akaogi H, Sakai S, Li M, Ochiai N. Concentrated autologous bone marrow aspirate transplantation treatment for corticosteroid-induced osteonecrosis of the femoral head in systemic lupus erythematosus. *Int Orthop* 2011; 35(6):823-829.
13. Gangji V, De M, V, Hauzeur JP. Autologous bone marrow cell implantation in the treatment of non-traumatic osteonecrosis of the femoral head: Five year follow-up of a prospective controlled study. *Bone* 2011; 49(5):1005-1009.
14. Kang JS, Moon KH, Kim BS *et al.* Clinical Results of Auto-Iliac Cancellous Bone Grafts Combined with Implantation of Autologous Bone Marrow Cells for Osteonecrosis of the Femoral Head: A Minimum 5-Year Follow-Up. *Yonsei Medical Journal* 2013; 54(2):510-515.
15. Nam KW, Kim YL, Yoo JJ, Koo KH, Yoon KS, Kim HJ. Fate of untreated asymptomatic osteonecrosis of the femoral head. *Journal of Bone & Joint Surgery* 2008; 90(3):477-484.
16. Koo KH, Kim R, Ko GH, Song HR, Jeong ST, Cho SH. Preventing collapse in early osteonecrosis of the femoral head. A randomised clinical trial of core decompression. *Journal of Bone & Joint Surgery, British Volume* 1995; 77(6):870-874.
17. McGrory BJ, York SC, Lorio R, *et al.* Current practices of AAHKS members in the treatment of adult osteonecrosis of the femoral head. *Journal of Bone & Joint Surgery Am.* 2007;89(6):1194-1204.
18. Von Stechow D, Drees P. Surgical treatment concepts for femoral head necrosis [in German]. *Orthopäde.* 2007;36(5):451-457.
19. Steinberg ME. Core decompression of the femoral head for avascular necrosis: indications and results. *Can J Surg.* 1995;38(suppl 1):S18-S24.
20. Simank HG, Brocai DR, Brill C, Lukoschek M. Comparison of results of core decompression and intertrochanteric osteotomy for nontraumatic osteonecrosis of the femoral head using Cox regression and survivorship analysis. *J Arthroplasty.* 2001;16(6):790-794.
21. Bellot F, Havet E, Gabrion A, Meunier W, Mertl P, de Lestang M. Core decompression of the femoral head for avascular necrosis [in French]. *Rev Chir Orthop Reparatrice Appar Mot.* 2005;91(2):114-123.
22. Lim YW, Kim YS, Lee JW, Kwon SY. Stem cell implantation for osteonecrosis of the femoral head. *Exp Mol Med.* 2013;45:e61.
23. Beckmann J, Schmidt T, Schaumburger J, *et al.* Infusion, core decompression, or infusion following core decompression in the treatment of bone edema syndrome and early avascular osteonecrosis of the femoral head. *Rheumatol Int.* 2013;33(6):1561-1565.
24. Al Omran A. Multiple drilling compared with standard core decompression for avascular necrosis of the femoral head in sickle cell disease patients. *Arch Orthop Trauma Surg.* 2013;133(5):609-613.
25. Soohoo NF, Vyas S, Manunga J, Sharifi H, Kominski G, Lieberman JR. Cost-effectiveness analysis of core decompression. *J Arthroplasty.* 2006;21(5):670-681.
26. Martin J, Houdek M, Sierra R. Use of concentrated bone marrow aspirate and platelet rich plasma during minimally invasive decompression of the femoral head in the treatment of osteonecrosis. *Croat Med J.* 2013; 54:219-24.

All content herein is protected by copyright, trademarks and other intellectual property rights owned by or licensed to Biomet Inc. or its affiliates unless otherwise indicated, and must not be redistributed, duplicated or disclosed, in whole or in part, without the express written consent of Biomet.

This material is intended for health care professionals and the Biomet sales force. Distribution to any other recipient is prohibited.

For complete product information, including indications, contraindications, warnings, precautions, and potential adverse effects, see the package insert and www.Biomet.com.

BIOMET
BIOLOGICS

One Surgeon. One Patient.

©2014 Biomet Biologics • Form No. BMET1081.0 • REV0914



Legal Manufacturer
Biomet Biologics
56 E. Bell Drive
P.O. Box 587
Warsaw, Indiana 46581-0587
USA

www.biomet.com